

A systematic review of the role of non-magnified endoscopy for the assessment of *H. pylori* infection




Authors

Ben Glover¹, Julian Teare¹, Nisha Patel²

Institutions

- 1 Imperial College London Department of Surgery and Cancer – Surgery and Cancer, London, England, UK
- 2 Imperial College London Department of Surgery and Cancer – Gastroenterology, London, England, UK

submitted 14.3.2019

accepted after revision 11.6.2019

Bibliography

DOI <https://doi.org/10.1055/a-0999-5252> |
 Endoscopy International Open 2020; 08: E105–E114
 © Georg Thieme Verlag KG Stuttgart · New York
 eISSN 2196-9736

Corresponding author

Dr. Nisha Patel, MBBS, BSc, PhD, Imperial College Healthcare NHS Trust, Department of Gastroenterology, Charing Cross Hospital, Fulham Palace Rd, Hammersmith W6 8RF, United Kingdom of Great Britain and Northern Ireland
nisha.patel8@nhs.net

ABSTRACT

Background and study aims There is growing interest in the endoscopic recognition of *Helicobacter pylori* infection, and application to routine practice. We present a systematic review of the current literature regarding diagnosis of

H. pylori during standard (non-magnified) endoscopy, including adjuncts such as image enhancement and computer-aided diagnosis.

Method The Medline and Cochrane databases were searched for studies investigating performance of non-magnified optical diagnosis for *H. pylori*, or those which characterized mucosal features associated with *H. pylori* infection. Studies were preferred with a validated reference test as the comparator, although they were included if at least one validated reference test was used.

Results Twenty suitable studies were identified and included for analysis. In total, 4,703 patients underwent investigation including white light endoscopy, narrow band imaging, i-scan, blue-laser imaging, and computer-aided diagnostic techniques. The endoscopic features of *H. pylori* infection observed using each modality are discussed and diagnostic accuracies reported. The regular arrangement of collecting venules (RAC) is an important predictor of the *H. pylori*-naïve stomach. “Mosaic” and “mottled” patterns have a positive association with *H. pylori* infection. The “cracked” pattern may be a predictor of an *H. pylori*-negative stomach following eradication.

Conclusions This review summarizes current progress made in endoscopic diagnosis of *H. pylori* infection. At present there is no single diagnostic approach that provides validated diagnostic accuracy. Further prospective studies are required, as is development of a validated classification system. Early studies in computer-aided diagnosis suggest potential for a high level of accuracy but real-time results are awaited.

Introduction

H. pylori is a common global pathogen, and infection is a known risk factor for gastric disorders including gastritis, peptic ulcer, and adenocarcinoma [1]. Diagnosis of *H. pylori* infection identifies patients at higher risk of these conditions and allows eradication therapy to be initiated, with resultant reduction of morbidity, including development of gastric cancer [2]. Conventional diagnostic tests for *H. pylori* include noninvasive methods such as stool antigen testing, serology, or the urea breath test. These deliver a high level of accuracy regarding *H. pylori* status, but do not provide endoscopic information regarding

the gastric mucosa and any abnormality. Invasive investigations for *H. pylori* include the rapid urease test, tissue microscopy, and tissue culture. Due to the focal or patchy nature of *H. pylori* infection, there is potential for sampling error and diagnostic inaccuracy [3].

There is potential benefit, therefore, from being able to endoscopically predict presence or absence of *H. pylori* within an area of gastric mucosa. An approach with sufficient diagnostic accuracy could distinguish areas of infected mucosa and allow targeted biopsy, with greater diagnostic yield from the invasive tests for *H. pylori*. It could even be possible to avoid the need for biopsy if infection could be reliably predicted. Further-

more, endoscopic appearance of the stomach may be altered following eradication of *H. pylori* and it is therefore important to be able to distinguish these changes from infected or *H. pylori*-naïve mucosa. Modern endoscopic platforms offer high-resolution images and the benefit of image-enhanced endoscopy (IEE) techniques, to allow inspection of the gastric mucosa at a level of detail not previously possible [4].

A recent Chinese meta-analysis investigated the diagnostic accuracy of magnifying endoscopy for *H. pylori* infection, both with and without IEE or chromoendoscopy [5]. The results suggest that the optimum method of diagnosis includes assessment of pit and vascular patterns, and that this approach is most accurate in the gastric body, compared to the antrum. However, magnifying endoscopy is less commonly used by western endoscopists, and is typically employed in specialist centers by expert operators. Diagnosis of *H. pylori* by non-magnifying endoscopy would therefore be of great interest to the general endoscopist, should it be found to be accurate and reproducible. Initial studies in non-magnifying endoscopy found disappointing results, with low sensitivity (18%–75%) and poor inter-operator agreement [6–8]. These studies were performed using endoscopic equipment with lower resolution than is currently in general use, and were unable to assess fine vascular patterns; gross morphology of the gastric mucosa was examined instead. With the advent of high-resolution endoscopic platforms from the major manufacturers, more recent studies have attempted to further investigate the diagnostic performance of high-resolution, non-magnified endoscopic examination for presence of *H. pylori* infection. We will discuss the current literature and relevant studies, including the impact of IEE and future developments, which include second-generation IEE systems such as blue laser imaging (BLI) and linked Color imaging (LCI). In addition to this, we discuss the exciting advances in computer-aided diagnosis (CAD), made possible by modern high-quality endoscopic images, combined with machine-learning processes.

Method

Search strategy

This review was registered with the PROSPERO register of systematic reviews (No.CRD42019123413). We systematically searched the databases of Medline and the Cochrane Library to identify relevant articles. The search terms “*Helicobacter pylori*,” “*H. pylori*,” “HP,” and “gastritis” were combined with the search terms “narrow band,” “i-scan,” “iscan,” “narrowband,” “optical biopsy,” “image enhanc*,” “IEE,” and “chromoendoscopy.” After scanning the titles and abstracts, articles were excluded if they did not meet the inclusion criteria. The abstracts and full text of the remaining articles were read, and a secondary search of the references was performed for any eligible studies that had been missed by the original search. A summary of the included studies is shown in ► **Table 1**. On review of the included studies, there was a high degree of heterogeneity, and many of the studies were descriptive rather than diagnostic. It was therefore decided that statistical analysis of diagnostic accuracy would not be possible, and results would not be illuminating.

Selection of studies for review:

The inclusion criteria were as follows:

- Endoscopy was used for visual diagnosis of *H. pylori* infection, or description of endoscopic features that could predict infection.
- The following reference standards were applied: Histological examination, serology, stool antigen testing, rapid urease test (RUT), or urea breath test (UBT). Studies with two or more of these methods used for diagnosis were preferred, but all studies using these reference standards were considered.
- The study was available in English.

The exclusion criteria were as follows:

- Magnified endoscopy alone was studied.
- Studies that overlapped the data already included, without adding new analysis.
- Studies without original research (review articles, opinion letters, comments)

Results

Study characteristics and summary of results for the studies are presented in ► **Table 1**. White-light endoscopy (WLE) has demonstrated the RAC, and suggested it confers a negative predictive value (NPV) of >90% for *H. pylori* infection. Abnormal patterns including antral nodularity and mosaic patterns are also visible using WLE, although diagnostic predictive power of these patterns is poor for predicting *H. pylori* positive status. Abnormal mucosal patterns predictive of current *H. pylori* infection include mosaic, mottled or spotty appearances.

Narrow-band imaging (NBI) has further characterized the mucosal features including rod- and cone-shaped gastric pits, prominent gastric sulci, ground glass appearance, dark brown patches with a blueish margin, and yellowish-white nodules (identified as lymphoid follicles). Again, these have shown good sensitivity and specificity for *H. pylori* infection but have not yet been validated in a prospective patient series.

A pilot study of i-scan has suggested that it is superior for identifying features of *H. pylori* infection vs white light alone.

A “cracked” mucosal appearance has been identified using modern high-resolution BLI equipment, and may represent the appearance of the mucosa after eradication of *H. pylori* infection.

CAD techniques have shown high levels of diagnostic accuracy for distinguishing between images of *H. pylori* infected mucosa, and *H. pylori* negative mucosa.

White-light endoscopy

Endoscopic examination under white light is the basic diagnostic modality during a routine upper GI endoscopy. It would therefore be desirable to be able to identify characteristics of both *H. pylori* infection, and of the *H. pylori* negative stomach under white light endoscopy (WLE).

Early studies in endoscopic diagnosis of *H. pylori* were performed with standard-definition endoscopic equipment; in 2003 Redéen et al. identified several potential endoscopic fea-

► **Table 1** Summary of study characteristics. Ordered by primary imaging modality, and date of publication.

Author	Year	Country	Imaging modality	Reference standard	Number of patients	Mucosal criteria investigated	Diagnostic accuracy
Redeen et al.	2003	Sweden	WLE	Histology, rapid urease test	488	Identified features including the absence of corpal rugae, erythema (diffuse, spotty, linear), gastric erosions and presence of visible vessels.	Showed sensitivity 75 % and specificity 63 % for diagnosis of current <i>H. pylori</i> infection. Image assessment was conducted retrospectively.
Yan et al.	2010	China	WLE	Histology, rapid urease test	112	Categorised four gastric mucosal patterns, including the RAC, cleft-like mucosa, mosaic, and mosaic with focal hyperaemia.	The presence of either of the two "mosaic" patterns were reported as having sensitivity and specificity of 100 % and 86 % for the presence of <i>H. pylori</i> -positive status. The RAC was reported as showing sensitivity of 20 % and specificity of 100 % for prediction of <i>H. pylori</i> negative status. Patient recruitment was prospective, but image analysis was retrospective.
Alaboudy et al.	2011	Japan	WLE	Histology, urea breath test	402	Investigated the RAC, suggested that presence of RAC is likely to exclude <i>H. pylori</i> infection.	RAC shows sensitivity and negative predictive value of 94.7 % and 98.1 % in patients under the age of 60. In patients over the age of 60, these fall to 80 % and 93 %.
Cho et al.	2013	Korea	WLE	Histology, rapid urease test	621	Categorised four distinct mucosal appearances including the RAC, mosaic pattern, diffuse homogeneous redness and 'atypical'.	The presence of any of the "abnormal" mucosal patterns predicted <i>H. pylori</i> infection with sensitivity 93.3 %, specificity 89.1 %. Patient recruitment was prospective, and image analysis was retrospective.
Watanabe et al.	2013	Japan	WLE	Histology, serology, rapid urease test	77	Identified that the diagnostic accuracy is greatest in <i>H. pylori</i> naïve patients, and declines in patients with previous <i>H. pylori</i> eradication. Also demonstrated good inter-operator agreement for features of <i>H. pylori</i> infection and a fast learning curve.	In the <i>H. pylori</i> negative stomach, the diagnostic accuracy was 88.9 %, although this fell to 62.1 % for patients with current <i>H. pylori</i> infection, and to 55.8 % for patients with eradicated <i>H. pylori</i> .
Gomes et al.	2016	Brazil	WLE	Histology, rapid urease test	339	Identified RAC, streaky erythema, fundic gland polyps and mucosal atrophy as negative predictors for <i>H. pylori</i> infection.	The factors found to be most strongly associated with infection were antral nodularity (26.9 %), raised erosion (15.38 %), and a mosaic pattern in the body (21.2 %). Patients were recruited prospectively, images were analysed retrospectively.
Matrakool et al.	2016	Thailand	WLE	Histology, rapid urease test	200	Classified mucosal morphology into four subtypes including RAC, clefts, mosaic, and mosaic with focal hyperaemia.	Assessed using a similar classification as Yan et al. Presence of RAC or clefts (Type I or II) predicted <i>H. pylori</i> negative status with 85 % accuracy. Presence of either mosaic pattern predicted <i>H. pylori</i> positive status with 92 % accuracy.

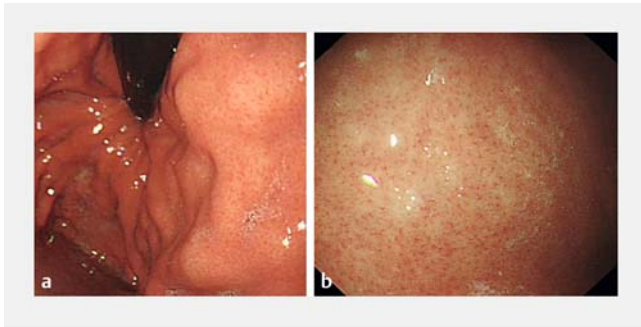
► **Table 1** (Continuation)

Author	Year	Country	Imaging modality	Reference standard	Number of patients	Mucosal criteria investigated	Diagnostic accuracy
Alaboudy et al.	2011	Japan	NBI	Histology	20	Defined five distinct mucosal patterns under NBI including RAC. Abnormal mucosa predicted <i>H. pylori</i> positive, and RAC predicted <i>H. pylori</i> negative.	Patients were selected for biopsy based on mucosal appearances. The RAC was associated with histologically normal mucosa. The cone-shaped, rod-shaped, ground-glass and dark brown patches mucosal patterns were associated with histological evidence of <i>H. pylori</i> infection and a degree of neutrophil or lymphocyte infiltration.
Özgür et al.	2015	Turkey	NBI	Urea breath test, rapid urease test, tissue culture	165	Study in paediatric population. Mucosal appearances classified according to Alaboudy et al.	Patients were recruited prospectively. The mucosal changes described by Alaboudy were further visualised under NBI. Sensitivity of 92.9% was found for <i>H. pylori</i> infection, in patients with abnormal gastric mucosa. Specificity was 62.4%.
Tongta-wee et al. (1)	2015	Thailand	NBI	Histology, rapid urease test	200	Proposed five mucosal patterns including RAC, cone-shaped gastric pits, rod-shaped pits with sulci, ground-glass morphology, dark brown patches with blueish margin and irregular border.	The mucosal patterns described by Alaboudy were assessed retrospectively following endoscopy. Type 3,4,5 mucosal pattern showed sensitivity 94.3% and specificity 96.7% for predicting <i>H. pylori</i> positivity. Presence of RAC predicted <i>H. pylori</i> negative status in 100% of patients.
Tongta-wee et al. (2)	2015	Thailand	NBI	Histology, rapid urease test	500	Demonstrated increased diagnostic yield when NBI was used to select biopsy sites.	In the patient group with gastric biopsies targeted to areas of abnormal mucosa, sensitivity of 95.4% and specificity 97.3% were achieved. The non-targeted group were 93.0% and 88.6% respectively.
Pimental-Nunes et al.	2016	Portugal, Italy, Romania, USA, UK.	NBI	Histology	238	The first clinical trial to prospectively evaluate the ability of NBI features to predict <i>H. pylori</i> status. Primarily evaluated other gastric premalignant conditions.	The accuracy of white-light vs narrow-band imaging was not found to be significantly different (73% and 74% respectively). This is currently the only study to predict the diagnosis prospectively.
Hayashi et al.	2018	Japan	NBI	Histology, urea breath test	211	Characterised the features and significance of "yellowish-white nodules" (YWN) under NBI.	Defined that the YWN are likely to represent lymphoid follicles (96%) agreement with histology. Diagnostic predictions for <i>H. pylori</i> status were not made during this study.

► **Table 1** (Continuation)

Author	Year	Country	Imaging modality	Reference standard	Number of patients	Mucosal criteria investigated	Diagnostic accuracy
Sharma et al.	2018	India	I-scan	Rapid urease test	146	Assessed features including abnormal vascularity, mosaic pattern, pit pattern, spider web pattern and abnormal light reflex.	Currently the only study investigating i-scan imaging. Diagnostic accuracy was reported as greater than WLE, at 97% vs 78%. Rapid Urease Test was the only reported diagnostic reference standard.
Dohi et al.	2016	Japan	LCI	Histology, rapid urease test, serology, urea breath test	60	Retrospectively examined the diagnostic potential of a diffuse erythematous appearance of the fundus, under LCI.	Overall diagnostic accuracy for <i>H. pylori</i> positive or negative status was reported as 85.8% on this retrospective review of endoscopic images.
Nishikawa et al.	2017	Japan	BLI	Previous <i>H. Pylori</i> -positive	441	Classified mucosa in patients with atrophic gastritis into "spotty," "cracked" or "mottled" appearances under BLI.	The "spotty" pattern correlated with <i>H. pylori</i> infection in 86% of patients with active infection. Sensitivity and specificity were 95.3% and 86.5%. The 'cracked' pattern was observed in patients with previous <i>H. pylori</i> infection, during inspection at post-eradication endoscopy.
Chen et al.	2018	Taiwan	LCI	Histology, urea breath test	122	Applied the classification of Dohi et al. prospectively, with both LCI and magnified LCI.	Diagnostic accuracy of non-magnified LCI was 78.4%, with sensitivity and specificity of 70.8% and 91.3% respectively. Diagnostic accuracy was not significantly different from magnified-LCI.
Itoh et al.	2017	Japan	CAD (WLE)	Serology	139	149 images of mucosal patterns from 139 patients were used to train a convolutional neural network to identify <i>H. pylori</i> status.	Presence of <i>H. pylori</i> positivity was detected by the CNN with sensitivity of 86.7% and specificity of 86.7%. The AUC was 0.956.
Shichijo et al.	2017	Japan	CAD (WLE)	Serology, stool antigen, urea breath test	N/K	32,208 images of mucosal patterns were used for training of a convolutional neural network (CNN) to identify <i>H. pylori</i> status.	Retrospective analysis of endoscopic images was performed. Diagnostic accuracy of 87.7% was achieved by the CNN, compared with 82.4% for human endoscopists.
Nakashima et al.	2018	Japan	CAD (BLI, LCI)	Serology	222	Approximately 2,000 images were used to train a CNN to identify <i>H. pylori</i> status. The artificial intelligence could also produce 'heat maps to show the region of interest.	Automated analysis was undertaken of images obtained under WLE, with sensitivity and specificity of 66.7% and 60.0%. Under BLI-bright and LCI modes, sensitivity increased to 96.7%, and specificity increased to 86.7% for BLI-bright and 83.3% for LCI.

WLE, white light endoscopy; RAC, regular arrangement of collecting vessels; NBI, narrow-band imaging; YWN, yellowish-white nodules; LCI, linked color imaging; CAD, computer-aided diagnosis; BLI, blue laser imaging; CNN, convolutional neural network.

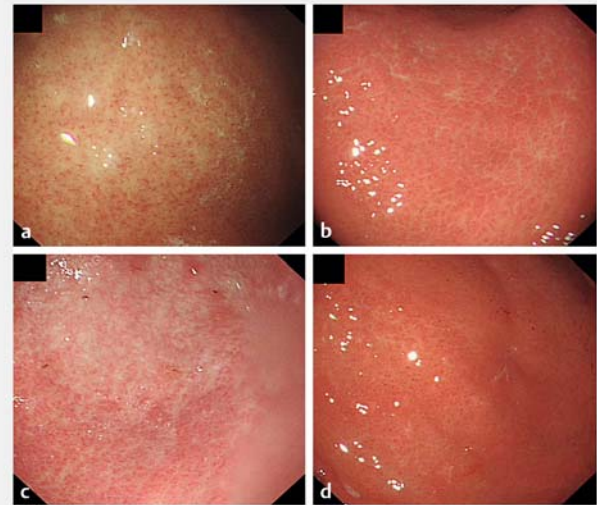


► **Fig. 1** Regular arrangement of collecting venules. **a** RAC present in the upper gastric body. **b** RAC present in the lower gastric body.

tures of *H. pylori* by logistic regression analysis, including an abnormal antral texture, a mammillated corpus surface, and antral erosions as likely predictive factors for presence of *H. pylori*. When applied prospectively, however, the sensitivity and specificity of these features was found to be only 75% and 63% [6]. Another study by Laine et al. identified antral nodularity as a strongly predictive factor for *H. pylori* infection (PPV 90%) and found good inter-operator agreement [7]. Importantly, in 2002 Yagi et al. described “minute points seen at regular intervals” in the stomach of *H. pylori*-negative patients. This has been characterized as the “regular arrangement of collecting venules” (RAC), presence of which was reported as showing 93.8% sensitivity for diagnosing and *H. pylori*-negative status [9]. Further studies in children and adolescents by Machado et al. in 2008 agreed that the positive finding of RAC is strongly predictive of *H. pylori*-negative status, particularly in the absence of antral nodularity [10]. Further analysis of endoscopic images by Alaboudy et al. has supported the hypothesis that presence of RAC suggests absence of *H. pylori* infection, but also notes that the RAC may become less visible with increasing age, requiring caution in its interpretation for older patients [11]. ► **Fig. 1** shows the RAC present within a normal stomach, at the upper and lower gastric body.

In 2010, Yan et al. performed a study using high-resolution WLE in 112 patients experiencing dyspepsia to establish a classification of the mucosal patterns in the gastric corpus associated with *H. pylori* infection. This reported a “cleft-like” pattern, a “regular arrangement of red dots,” a “mosaic appearance” and a “mosaic appearance with hyperaemia.” The combined sensitivity, specificity, and NPV for *H. pylori* infection of the two “mosaic” patterns was reported as 100%, 86%, and 100%, respectively [12]. Although patient recruitment was prospective, analysis of the images and categorization was performed retrospectively, after the time of endoscopy. A similar classification was developed by Matrakool et al., who also demonstrated good correlation between the different endoscopic appearances and histological grade of inflammation [13].

Further characterization of the gastric mucosa in *H. pylori* was studied by Cho et al. in 2013, using prospective recruitment of 617 patients and close examination of the gastric corpus. Four distinct mucosal patterns were again identified; the “regular arrangement of collecting vessels” (RAC) which was re-



► **Fig. 2** Mucosal patterns observed in the gastric corpus. **a** Normal, regular arrangement of collecting venules (RAC) pattern seen as numerous minute red dots. **b** Mosaic-like appearance characterized by prominent, swollen areas gastricae with deeper furrows or snake skin appearance. **c** Diffuse homogenous redness. **d** Atypical pattern of irregular redness with groove.

garded as normal, a “mosaic-like” appearance, “diffuse homogeneous redness” and “irregular redness with groove,” which were regarded as abnormal. Presence of *H. pylori* infection could be predicted with a sensitivity of 93.3%, specificity of 89.1%, and overall accuracy of 91.6% in a patient with any of the “abnormal” patterns [14]. The mucosal appearances are shown in ► **Fig. 2**.

Further characteristics of the *H. pylori*-positive stomach were explored by Gomes et al. in 2016, who agreed that *H. pylori* infection is associated with antral nodularity and mosaic pattern in the corpus [15].

Another important consideration in assessment of *H. pylori* status is distinguishing between patients without previous *H. pylori* infection and those with eradicated infection. A study of endoscopic images from 77 patients with dyspepsia was performed in 2013 by Watanabe et al. and grouped patients as *H. pylori*-naïve, *H. pylori*-infected, and *H. pylori*-eradicated. Diagnostic accuracy for *H. pylori*-naïve patients was 89%, falling to 62.1% for infected patients and 55.8% for *H. pylori*-eradicated patients [16]. The role of mucosal pattern recognition in diagnosis of *H. pylori* is still developing, and although the potential for high diagnostic accuracy has been demonstrated in studies of endoscopic images, more robust prospective trials are required to validate the accuracy of diagnostic predictions. An important area for development would be introduction of a unified classification system for prediction of *H. pylori* positivity and negativity, and improved understanding of the features of the stomach after *H. pylori* eradication. The RAC has been identified as an important predictor of the *H. pylori*-naïve stomach, and is clearly visible under WLE, without additional magnification.

Narrow-band Imaging

The current generation of endoscopes from Olympus (Tokyo, Japan) incorporate optical filters, which can be activated during endoscopy to produce an altered-color image. There is interest in using this technique for NBI to further interrogate the mucosa for additional diagnostic information, not apparent using WLE.

NBI assessment of *H. pylori* was investigated in 2011 by Alaboudy et al., who retrospectively assessed endoscopic images of 300 patients with known *H. pylori*, and devised a classification including five distinct mucosal appearances (Type 1: RAC present, Type 2: Cone-shaped gastric pits, Type 3: Rod-shaped gastric pits, prominent sulci, Type 4: Ground-glass appearance, Type 5: Dark brown patches, blueish margin, irregular border) [17]. Subsequently, 20 volunteers underwent endoscopy with biopsy, showing the RAC was also identifiable under NBI, and predicted *H. pylori*-negative status.

Further predictors of *H. pylori* status were investigated by Hayashi et al. In 2013, with a retrospective study of 211 patients with confirmed *H. pylori*, to investigate the significance of the “yellowish-white nodules” (YWN) which had been noted to appear frequently in the *H. pylori*-positive stomach and were postulated to correspond with lymphoid follicles [18]. These were examined under white light and NBI (also under magnified NBI) and seen to be about 0.5 to 1 mm in diameter. Presence of YWN had a high specificity (96%) for the histological finding of lymphoid follicles and may therefore act as a surrogate marker for the histological finding of nodular gastritis, associated with *H. pylori* infection.

Also in 2013, a prospective study in pediatric patients was performed by Özgür et al. to further investigate NBI findings associated with *H. pylori* infection [19]. Patients with dyspepsia or abdominal pain whose *H. pylori* status was unknown were enrolled and underwent endoscopic examination with white light and NBI. Endoscopic features of interest included findings of gastritis, nodular gastritis, or ulceration. This study found a greater proportion of mucosal changes in patients with *H. pylori* infection, and furthermore discovered that these changes were more readily identifiable under NBI than WLE. A sensitivity of 92.9% was achieved for NBI examination, with specificity 62.4%.

Attempts were made to define diagnostic accuracy of the observable features in an *H. pylori*-infected stomach by Tongta- wee et al. in 2014 [20]. Two hundred patients with dyspepsia were examined endoscopically with white light and NBI, and the observed mucosal patterns were characterized according to the classification developed by Alaboudy et al. Presence of Type 3, 4 or 5 mucosal patterns was found to have a sensitivity of 94.3%, with specificity of 96.7%, for predicting *H. pylori* positivity. It should be further noted that 100% of patients with RAC present (35/35) were found to be *H. pylori*-negative. A further study by the same group recruited 500 patients to assess the benefit of using a “site-specific biopsy” of abnormal mucosa rather than random biopsy for the diagnosis of *H. pylori*. Increases in sensitivity and specificity to 95.4% and 97.3% were noted (from 93.0% and 88.6% respectively) [21].

The first prospective study for real-time use of both WLE and NBI was performed in 2014 and 2015 by Pimental-Nunes et al. This was a multicenter study involving sites in Portugal, Italy, Romania, the United States, and the UK [22]. The study primarily investigated diagnosis of premalignant gastric lesions including metaplasia and dysplasia, and introduced an endoscopic classification system for these lesions, which included *H. pylori* gastritis (characterized as variable vascular density, with a normal corpus mucosa). A total of 238 patients were examined, first with WLE and then NBI. For diagnosis of *H. pylori* infection, the accuracy of WLE and NBI was similar (73% and 74% respectively). NBI showed slightly higher sensitivity and slightly reduced specificity, but this was not statistically significant. Although not the primary outcome of the study, this is the only study to have prospectively assessed diagnostic accuracy of NBI for *H. pylori* in real time.

The role of NBI in assessment of *H. pylori* infection continues to develop. The earliest study under clinical conditions has not shown accuracy enough to confidently diagnose *H. pylori* without biopsy or alternative diagnostic method, [22] but it may be that the benefits of NBI come from the more accurate identification of abnormal mucosa, allowing targeted biopsies to be obtained, and increasing their diagnostic yield.

i-scan digital chromoendoscopy

To date, only one study has been published investigating diagnostic accuracy of non-magnified i-scan, a digital image enhancement technique incorporated into endoscopes from Pentax Medical (Tokyo, Japan). This was a prospective pilot study in 2017 which recruited 146 patients with symptoms of dyspepsia. A greater proportion of patients were identified as showing endoscopic features of *H. pylori* under i-scan examination, (79/146, compared to 45/146 under WLE) and the overall diagnostic accuracy of i-scan was reported as 97%, compared with 78% for WLE. The diagnostic features used are not further elaborated. [23]

Comparable to NBI, i-scan offers the potential to gain more information from visual examination of the gastric mucosa, versus WLE, and is likely to develop a similar role. Newer endoscopic platforms from Pentax will integrate the second-generation “i-scan Optical Enhancement” (OE) which incorporates an optical filter and promises improved visual contrast.

Blue laser imaging and linked-color imaging

A recent innovation in endoscopic imaging is the LASEREO endoscopic platform, produced since 2013 by Fujifilm (Tokyo, Japan). This creates illumination by excitation of a phosphor at the endoscope tip, and can apply light from a second laser to create an altered color BLI mode [24]. In addition, the system incorporates LCI which further adjusts the colors and increases visual contrast.

The earliest study of LCI in *H. pylori* infection was performed by Dohi et al. in 2016. This was a retrospective review of endoscopic images using LCI, from 60 patients: 30 *H. pylori*-positive, and 30 negative after eradication [25]. The diagnostic criterion applied was a diffuse redness of the fundus, which the investigators anticipated would be accentuated by LCI. The overall di-

agnostic accuracy of LCI for *H. pylori* was found to be 85.8%, and there was moderate–good agreement between expert and non-expert endoscopists.

Nishikawa et al. explored the diagnostic potential of BLI in 2017 by analysis of images obtained from 441 patients diagnosed with atrophic gastritis [26]. The mucosal patterns were classified as “spotty,” “cracked” or “mottled” on retrospective review of the images by expert endoscopists. The spotty pattern was found to correlate with active *H. pylori* infection (77/89 patients) and the authors also suggest that the cracked pattern may represent post-inflammatory change after *H. pylori* eradication, and the mottled pattern may represent intestinal metaplasia resulting from *H. pylori*-related gastritis.

The first real-time diagnostic study of LCI was performed in 2018 by Chen et al. and recruited 122 patients for examination by LCI, with WLE and magnified endoscopy as comparators [27]. Patients underwent WLE, followed by LCI, and then magnified WLE. The diagnostic criterion applied was absence of the RAC. Diagnostic accuracy of LCI was reported as 78.4%, with sensitivity and specificity of 70.8% and 81.3% respectively. This was not statistically different from examination under magnification, or if LCI and magnification were combined. Diagnostic accuracy of WLE alone was not reported in this study; it is unclear then if LCI provides an increase to diagnostic accuracy over standard endoscopy.

Computer-aided diagnosis and artificial intelligence

CAD is a rapidly progressing area within all endoscopic disciplines. Recent advances in processing power have permitted development of “deep learning” algorithms and convolutional neural networks (CNN), capable of analyzing an image for features including shapes, colors and textures. Developments in colonoscopy have shown the potential for lesion detection to be integrated into the endoscopic image seen by the operator [28], and there have been several studies investigating automated diagnosis of *H. pylori* infection by deep learning algorithms.

Early applications of these techniques were developed by Itoh et al. in 2017, who produced a deep learning algorithm based on the GoogLeNet CNN. This was trained using 149 endoscopic images under WLE from patients with known *H. pylori* status. When applied to a test series of 30 new endoscopic images, the CNN achieved a diagnostic sensitivity and specificity of 86.7% and 86.7% [29].

Shichijo et al. developed further CNNs capable of diagnosing *H. pylori* based on endoscopic images, in 2017 [30]. Two neural networks were trained, one on a database of 32,208 WLE images obtained from patients with known *H. pylori* status, and the second on images classified by anatomical location in the upper gastrointestinal tract. Diagnostic performance of the combined CNN was compared with 23 endoscopists for analyzing a third set of 11,481 test images. An accuracy of 87.7% was achieved by the CNN, compared with 82.4% for the endoscopists. It was also notable that the time taken to produce the diagnoses was dramatically different, at 194 seconds for the CNN, compared with 230 minutes for the human endoscopists, demonstrating the potential for rapid CAD as an adjunctive tool during endoscopy.

CAD has also been studied for the newer endoscopic platforms; Nakashima et al. produced a CAD algorithm trained on images obtained using BLI-bright mode and LCI in addition to WLE [31.] This was a “transfer learning” model rather than a fully developed CNN, and was trained on a series of 162 images for each modality, then tested on a further 60 images for each. Sensitivity and specificity for WLE under CAD analysis were 66.7% and 60.0%, respectively, but as anticipated by the authors, there was a dramatic increase when the BLI-bright and LCI images were analyzed, with sensitivity 96.7% for each modality, and specificity of 86.7% for BLI-bright, and 83.3% for LCI. Furthermore, the algorithm produced “heat maps” demonstrating the region of interest to the artificial intelligence. This technique could be readily adapted to facilitate a strategy of targeted biopsy.

Discussion

Developments in quality of endoscopic imaging have presented the opportunity to advance frontiers of endoscopic diagnosis, and it has been well demonstrated that meticulous examination of the gastric mucosa can yield information regarding the *H. pylori* status of a patient. The current dilemma therefore concerns the appropriate way to apply this knowledge. It would be desirable to produce an accurate real-time diagnosis of *H. pylori* status, which might prompt further testing or even negate the requirement for biopsy (for urease testing, histological examination or tissue culture) if an appropriate level of diagnostic accuracy is achieved. This degree of accuracy may be difficult to demonstrate in clinical practice, however, due to factors such as the heterogeneity of patient groups, concomitant medications, previous *H. pylori* infection, and variable distribution of infection. In addition, these tests are readily available in clinical use, and are relatively inexpensive. The acceptability of providing an “optical biopsy” diagnosis is unproven, for patients and clinicians.

The studies included in this review use various methods as their “reference standard” for presence or absence of *H. pylori* infection. Serology, urea breath test, and fecal antigen testing were preferred as the confirmatory test, as there is potential for diagnostic inaccuracy from tests requiring biopsy (rapid urease test, tissue microscopy or culture). These may introduce sampling error, due to the nature of *H. pylori* infection, which may be patchy and can be missed by random biopsy sampling. Some of the studies included in this review use these methods, although the biopsy sampling protocol is not always fully elaborated. ► **Table 1** lists the reference standards applied in each study.

A potential benefit from understanding mucosal patterns associated with different *H. pylori* states could be in identifying areas of mucosa that are the most likely to harbor *H. pylori*, and thereby increase diagnostic yield of biopsy sampling by taking targeted, rather than random biopsies. Furthermore, an understanding of the different mucosal appearances will allow patients to be categorized as *H. pylori*-naïve, infected, or eradicated, and future studies on diagnostic accuracy should include these categories.

Several different image enhancement modalities were investigated for their ability to better define mucosal features. Six of these studies investigated NBI (Olympus), three studies investigated BLI and LCI imaging modes (Fuji) and one study investigated i-scan (Pentax). Each of these technologies aims to enhance the contrast of mucosal surface features, and the resultant altered color images are similar, but not entirely the same. There is little information about the preferred imaging modality and practice of endoscopists, but if a unified approach to assessment of *H. pylori* is to be developed, then it will be important to understand similarities and differences between the images from the different technologies. This could be achieved by studies with multiple patient groups, allocated to different equipment, or could perhaps be assessed by review of images taken at endoscopy, to assess the intra- and inter-operator agreement for different technologies.

In common with other areas of endoscopic practice, CAD of *H. pylori* is a rapidly developing field, with great potential to aid clinicians. Early studies demonstrate very high diagnostic accuracy, although it must be remembered that these are under optimized conditions, and tested on static images rather than real-time, in vivo. The “deep learning” of convolutional neural networks is commonly described as a “black box” system – the input (image) and the output (diagnosis) are known, but the processes by which the diagnosis is achieved are not. Understanding which characteristics are identified by the CNN can allow a new appreciation of the changes associated with disease. There are different methods used to understand the logic processes of a CNN, for example, the imaging “heat maps” illustrate what parts of an image the CNN has used for discrimination of *H. pylori* status. Other methods include altering the inputs given to the algorithm and studying changes to the outputs. As deep learning algorithms come to play an increasing role in diagnosis, it will become increasingly important to “open the black box” to understand the functioning within, for academic, legal and ethical purposes. [32]

Conclusions

Several features of the stomach mucosa can be identified without specialist endoscopy as predictors of *H. pylori* status. Importantly, presence of RAC may rule out current or previous *H. pylori* infection with sensitivity of >90%. This has been supported by multiple image analyses, although has not yet been validated prospectively. Studies of automated image analysis have demonstrated the ability to distinguish between different *H. pylori* status, although this research is currently at the stage of retrospective analysis only.

The aim of future research should now be to validate diagnostic accuracy of the discovered features and the CAD approaches, with the aim of proposing a simple classification system for endoscopic prediction of *H. pylori* status. This should attempt to stratify endoscopic appearances of an area of mucosa into “low probability” or “high probability” of harboring *H. pylori* infection. Future research should include robust prospective clinical trials in which the diagnosis is made during the endoscopic procedure, whether made by a clinician or by a

CAD technique. Ideally, patients would be categorized as *H. pylori*-naïve, infected or eradicated using reliable methods such as serology and urea breath testing. External validity of a proposed classification would be maximized by studying a heterogeneous group of patients, as many of the studies currently available exclude patients with previous *H. pylori*, or patients taking proton pump inhibitors. A classification system would also be most useful if it could be applied with confidence when using all forms of image enhancement, as well as WLE. Adoption of such a classification system could improve endoscopists’ confidence in their diagnoses and improve diagnostic yield of biopsy samples. The role of CAD may be as an adjunct to clinical judgement, and to improve the confidence of clinical decisions.

Competing interests

None

References

- [1] Venerito M, Vasapolli R, Rokkas T et al. Gastric cancer: epidemiology, prevention, and therapy. *Helicobacter* 2018; 23 : (Suppl. 01): e12518
- [2] Wong BC, Lam SK, Wong WM et al. *Helicobacter pylori* eradication to prevent gastric cancer in a high-risk region of China: a randomized controlled trial. *JAMA* 2004; 291: 187 – 194
- [3] Cho JH, Jeon SR, Kim HG et al. Factors for improving the diagnostic efficiency of the rapid urease test from the gastric corpus. *Scand J Gastroenterol* 2017; 52: 1320 – 1325
- [4] Skrebinska S, Megraud F, Bessede E. Diagnosis of *Helicobacter pylori* infection. *Helicobacter* 2018; 23 : (Suppl. 01): e12515
- [5] Qi Q, Guo C, Ji R et al. Diagnostic performance of magnifying endoscopy for *Helicobacter pylori* Infection: A meta-analysis. *PLoS ONE* 2016; 11: e0168201
- [6] Bah A, Saraga E, Armstrong D et al. Endoscopic features of *Helicobacter pylori*-related gastritis. *Endoscopy* 1995; 27: 593 – 596
- [7] Laine L, Cohen H, Sloane R et al. Interobserver agreement and predictive value of endoscopic findings for *H. pylori* and gastritis in normal volunteers. *Gastrointest Endosc* 1995; 42: 420 – 423
- [8] Redéen S, Petersson F, Jönsson K-Å et al. Relationship of gastroscopic features to histological findings in gastritis and *Helicobacter pylori* infection in a general population sample. *Endoscopy* 2003; 35: 946 – 950
- [9] Yagi K, Nakamura A, Sekine A. Characteristic endoscopic and magnified endoscopic findings in the normal stomach without *Helicobacter pylori* infection. *J Gastroenterol Hepatol* 2002; 17: 39 – 45
- [10] Machado RS, Viriato A, Kawakami E et al. The regular arrangement of collecting venules pattern evaluated by standard endoscopy and the absence of antrum nodularity are highly indicative of *Helicobacter pylori* uninfected gastric mucosa. *Dig Liver Dis* 2008; 40: 68 – 72
- [11] Alaboudy A, Elbahrawy A, Matsumoto S et al. Regular arrangement of collecting venules: Does patient age affect its accuracy? *World J Gastrointest Endosc* 2011; 3: 118 – 123
- [12] Yan SL, Wu ST, Chen CH et al. Mucosal patterns of *Helicobacter pylori*-related gastritis without atrophy in the gastric corpus using standard endoscopy. *World J Gastroenterol* 2010; 16: 496 – 500
- [13] Matrakool L, Tongtawee T, Bartpho T et al. Improved detection of *Helicobacter pylori* infection and premalignant gastric mucosa using conventional white light source gastroscopy. *APJCP* 2016; 17: 2099 – 2103

- [14] Cho JH, Chang YW, Jang JY et al. Close observation of gastric mucosal pattern by standard endoscopy can predict *Helicobacter pylori* infection status. *J Gastroenterol Hepatol* 2013; 28: 279–284
- [15] Gomes A, Skare TL, Prestes MA et al. Conventional videoendoscopy can identify *Helicobacter pylori* gastritis? *Arq Bras Cir Dig* 2016; 29: 73–76
- [16] Watanabe K, Nagata N, Shimbo T et al. Accuracy of endoscopic diagnosis of *Helicobacter pylori* infection according to level of endoscopic experience and the effect of training. *BMC Gastroenterol* 2013; 13: 128–135
- [17] Alaboudy AA, Elbahrawy A, Matsumoto S et al. Conventional narrow-band imaging has good correlation with histopathological severity of *Helicobacter pylori* gastritis. *Dig Dis Sci* 2011; 56: 1127–1130
- [18] Hayashi S, Imamura J, Kimura K et al. Endoscopic features of lymphoid follicles in *Helicobacter pylori*-associated chronic gastritis. *Dig Endosc* 2015; 27: 53–60
- [19] Ozgur T, Ozkan TB, Erdemir G et al. The diagnostic value of endoscopic narrow band imaging in helicobacter pylori gastritis in children. *Turk J Gastroenterol* 2015; 26: 112–116
- [20] Tongtawee T, Kaewpitoon S, Kaewpitoon N et al. Correlation between gastric mucosal morphologic patterns and histopathological severity of *Helicobacter pylori* associated gastritis using conventional narrow band imaging gastroscopy. *BioMed Res Int* 2015; 2015: 808505
- [21] Tongtawee T, Dechsukhum C, Leeansaksiri W et al. Improved detection of *Helicobacter pylori* infection and premalignant gastric mucosa using “site specific biopsy”: a randomized control clinical trial. *APJCP* 2015; 16: 8487–8490
- [22] Pimentel-Nunes P, Libanio D, Lage J et al. A multicenter prospective study of the real-time use of narrow-band imaging in the diagnosis of premalignant gastric conditions and lesions. *Endoscopy* 2016; 48: 723–730
- [23] Sharma VSaini S, Saini S et al. High efficacy of i-scan endoscopy in the diagnosis of *Helicobacter pylori* infection. *Clin Gastroenterol Hepatol* 2017; 15: 154
- [24] Morimoto Y, Kubo M, Kuramoto M et al. Development of a new generation endoscope system with lasers “LASEREO”. *Fujifilm Research And Development* 2013; 58: 1–6
- [25] Dohi O, Yagi N, Onozawa Y et al. Linked color imaging improves endoscopic diagnosis of active *Helicobacter pylori* infection. *Endosc Int Open* 2016: 04
- [26] Nishikawa Y. Classification of atrophic mucosal patterns on Blue LASER Imaging for endoscopic diagnosis of *Helicobacter pylori*-related gastritis: A retrospective, observational study. *PLoS One* 2018; 13: e0193197
- [27] Chen TH, Hsu CM, Cheng HT et al. Linked color imaging can help gastric *Helicobacter pylori* infection diagnosis during endoscopy. *JCMA* 2018; 81: 1033–1037
- [28] Urban G, Tripathi P, Alkayali T et al. Deep learning localizes and identifies polyps in real time with 96% accuracy in screening colonoscopy. *Gastroenterology* 2018; 155: 1069–1078.e1068
- [29] Itoh T, Kawahira H, Nakashima H et al. Deep learning analyzes *Helicobacter pylori* infection by upper gastrointestinal endoscopy images. *Endosc Int Open* 2018; 6: E139–144
- [30] Shichijo S, Nomura S, Aoyama K et al. Application of convolutional neural networks in the diagnosis of *Helicobacter pylori* infection based on endoscopic images. *EBioMedicine* 2017; 25: 106–111
- [31] Nakashima H, Kawahira H, Kawachi H et al. Artificial intelligence diagnosis of *Helicobacter pylori* infection using blue laser imaging-bright and linked color imaging: a single-center prospective study. *Ann Gastroenterol* 2018; 31: 462–468
- [32] Holm EA. In defense of the black box. *Science* 2019; 364: 26–27