

# Pathological Mechanisms and Clinical Features of Eosinophilic Chronic Rhinosinusitis in the Japanese Population

Sachio Takeno<sup>1</sup>, Katsuhiko Hirakawa<sup>1</sup> and Takashi Ishino<sup>1</sup>

## ABSTRACT

The overall pathological view of paranasal sinus inflammation in the Japanese population has profoundly changed in recent years. Eosinophilic chronic rhinosinusitis (ECRS) is a clinical entity of intractable chronic sinus inflammation accompanied by numerous infiltrations of activated eosinophils in the paranasal sinus mucosa and/or nasal polyps. Several pathologic processes are considered to act in concert to promote the accumulation of eosinophils in ECRS. They include infiltration of progenitor cells, increase in local IL-3, IL-5, IL-13, GM-CSF and eotaxin production, and upregulation of adhesion molecules. The role of nasal allergen sensitization and innate immunity responses in the sinus mucosa has also been proposed in the development of ECRS. Various pathogens including TLRs ligands may trigger an abnormal immune response at the mucosal surface. The objectives of ECRS management should focus directly on inhibition of local eosinophil infiltration. Surgical procedures include widely opening the bony wall septum of every affected sinus and mechanical removal of diseased mucosal lesion. The use of local and/or systemic steroids, leukotriene receptor antagonists, and Th2 cytokine antagonists is recommended. Local administration of steroids is a potent treatment strategy for preventing relapse of nasal polyposis and is considered to be the first-line treatment for ECRS patients.

## KEY WORDS

endoscopic sinus surgery, eosinophilic chronic rhinosinusitis, glucocorticoids, Toll-like receptor, transcription factors

## INTRODUCTION

Paranasal sinus infection still remains one of the most common diseases in Japan. Chronic sinusitis is an inflammatory disease defined as a paranasal sinus infection that has persisted for longer than 3 months. Due to the accumulation of considerable knowledge about the immunopathology of the disease, the overall pathological view of paranasal sinus infection has profoundly changed and evolved in recent decades. As has been revealed by the process of diagnosing the disease, there is a large degree of heterogeneity in the underlying pathophysiology and associated histological features.<sup>1-3</sup> The categorization of chronic sinusitis into subtypes may have important implications

for treatment and expected long-term outcomes. At the clinical symposium of the Annual Meeting of the Japanese Rhinological Society held in 2006, eosinophilic chronic rhinosinusitis (ECRS) was summarized as an entity of intractable chronic sinus inflammation accompanied by numerous infiltration of activated eosinophils in the paranasal sinus mucosa and/or nasal polyps (Table 1).

Although several theories on the causes of sinus tissue eosinophilia have been postulated, the original cause of eosinophil recruitment is unclear, especially in non allergic subjects.<sup>4-6</sup> Bronchial asthma (including aspirin-induced asthma) is known to often be concurrent with these cases. A Th2-type profile has been implicated as one of the dominant pathogenic proc-

<sup>1</sup>Department of Otolaryngology, Head and Neck Surgery, Division of Clinical Medical Science, Programs for Applied Biomedicine, Graduate School of Biomedical Sciences, Hiroshima University, Hiroshima, Japan.

Correspondence: Sachio Takeno, MD, PhD, Department of Otolar-

gology, Hiroshima University School of Medicine, Kasumi, 1-2-3, Minami-ku, Hiroshima 734-8551, Japan.

Email: [takeno@hiroshima-u.ac.jp](mailto:takeno@hiroshima-u.ac.jp)

Received 28 February 2010.

©2010 Japanese Society of Allergology

**Table 1** Clinical features of ECRS in Japan

- 1) Remarkable infiltration of activated eosinophils is histologically observed in the paranasal sinus mucosa and/or nasal polyps.
- 2) Adult onset cases are etiologically predominant.
- 3) Sinus disease tends to occur bilaterally.
- 4) Existence of multiple nasal polyps and characteristic mucus secretion with high viscosity.
- 5) Complication of atopic diathesis is not necessary.
- 6) Patients tend to show higher eosinophil count in the peripheral blood.
- 7) Persistent inflammation is more common in ethmoid sinus mucosa than in maxillary sinuses to which blockage of the ostiomeatal complex is related.
- 8) Complication of lower airway disease such as bronchial asthma is frequent.
- 9) Severe manifestation of olfactory dysfunction tends to occur in earlier stage.
- 10) Treatment with local/systemic steroids is effective as compared to low-dose macrolide therapy.

esses in ECRS with stimulation of the adaptive immune response. In this article, in order to gain an understanding of both the basic and clinical aspects of the disease, we attempted to assess the relative weight and role of various factors possibly involved in eosinophil infiltration into the sinus mucosa in ECRS patients among the Japanese population. Several societies have already proposed recommendations and guidelines for the management of patients with chronic rhinosinusitis and nasal polyposis based on evidence and expert opinion.<sup>1-3</sup> We feel that studies in Japanese populations may be helpful for gaining an understanding of the pathogenic mechanisms of ECRS.

### **CURRENT BASIS FOR THE CHARACTERIZATION OF ECRS**

The clinical significance of anatomic variants of human paranasal sinus systems causing a predisposition to sinus diseases through blockage of the ostiomeatal complex became a subject of controversy in the late 1990s (Fig. 1). Contrary to common belief, previous radiological studies using CT scan only confirmed the association between persistent chronic sinusitis, septal deviations and unusual deflexions of the uncinate process. They failed to present a significant association between the disease and most of the other anatomic variants (i.e., concha bullosa, paradoxical curve of the middle turbinate, pneumatized uncinate process, and Haller cells).<sup>7</sup> On the other hand, a close correlation has been noted between systemic or local eosinophil recruitment and the extent of sinus disease, as evaluated by computed tomography.<sup>8</sup> In this study, bronchial asthma, atopic diathesis, and age were also associated with extensive disease.

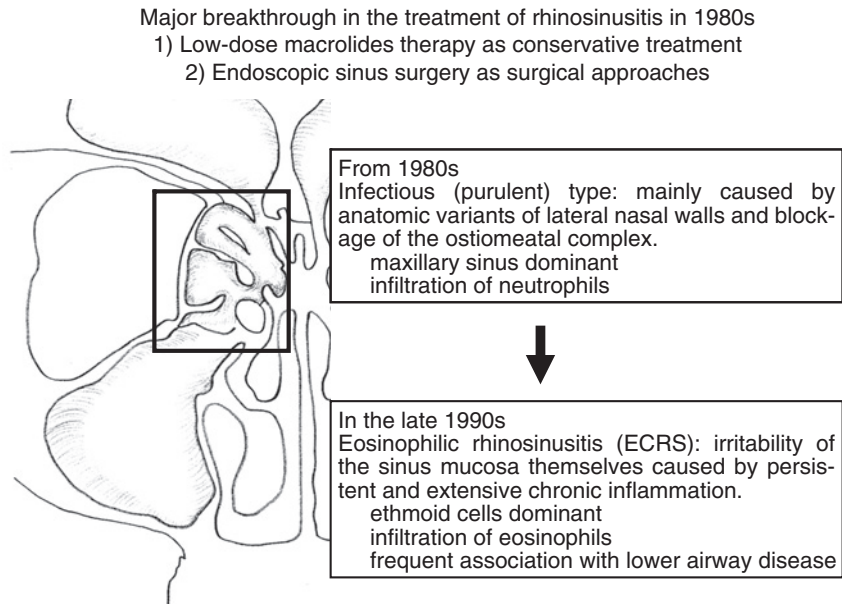
ECRS is at present characterized by unrestrained proliferation of eosinophils that form clusters in the mucosa, where they release toxic granules.<sup>9-12</sup> ECRS patients with a high percentage of activated EG2-positive cells had higher CT scores in the ethmoidal sinuses accompanied by severe manifestation of olfactory dysfunction.<sup>11</sup> The mechanisms by which eosinophilic inflammation damages the epithelium and con-

tributes to recurrent acute exacerbations in the disease have not been fully elucidated. Although several studies, including ours, have qualitatively and quantitatively provided data on the histopathological features of chronic rhinosinusitis, there are no standard levels of tissue eosinophil density to define ECRS.<sup>13</sup> Berger *et al.* previously defined sinusitis patients as having polypoid mucosa and eosinophilia (PME) according to a guideline based on gross microscopic assessment.<sup>14</sup> They observed a significant increase in the number of eosinophils in the PME group (median value of 33.5 cells/mm<sup>2</sup>) compared with in sinusitis patients with glandular hyperplasia.

### **THE ROLE OF ACTIVATED EOSINOPHILS IN ECRS PATHOLOGY**

Eosinophils are considered to play a major role in the pathogenesis of ECRS through the release of noxious secretory granules.<sup>10,11,15,16</sup> They release major basic protein, eosinophil-derived neurotoxin, eicosanoids, and various cytokines. The eosinophils histologically infiltrate into the epithelium out to the sinus cavity through the thickened basement membrane. Disruption of mucociliary clearance systems caused by the continuous eosinophilic inflammation eventually result in impaired immune capabilities and possible infectious damage to the host.<sup>17</sup> Several pathologic processes are considered to act in concert to promote the accumulation of eosinophils in ECRS.<sup>1</sup> They include infiltration of CD34+ eosinophil progenitor cells, increase in the local survival and activation of eosinophils, which is dependent on local IL-3, IL-5, IL-13 and GM-CSF production, upregulation of endothelial VCAM-1 and P-selectin, and production of C-C chemokines in epithelial cells and fibroblasts. Enhanced production of eotaxin-1, -2, and -3 by tissue eosinophils in Japanese ECRS patients has recently been reported, indicating the recruitment of eosinophils into the tissue by a self-amplifying process.<sup>18</sup>

There seem to be inter-racial differences in the immunopathologic features of chronic rhinosinusitis, indicating that distinct mechanisms may underlie the pathogenesis of nasal polyps between different ethnic



**Fig. 1** Changes of pathohistological backgrounds and clinical characteristics of paranasal sinus infection.

groups.<sup>19</sup> Kim *et al.* found that eosinophilic nasal polyposis accounted for only 33.3% of the 30 samples obtained from a Korean population.<sup>20</sup> Cao *et al.* recently investigated the immunopathologic profiles of chronic rhinosinusitis with nasal polyps (CRSwNP) and without nasal polyps (CRSsNP) in a nonwhite (adult Chinese) population.<sup>19</sup> More than half (53.6%) of the CRSwNP patients presented with non-eosinophilic inflammation. The authors observed impaired regulatory T cell function and enhanced TH1/TH2/TH17 responses in both groups. CRSsNP was confirmed to be a predominant TH1 milieu, whereas TH2-skewed inflammation with predominant TH17 reactions was demonstrated only in eosinophilic CRSwNP, but not in non-eosinophilic CRSwNP. TH17, a newly defined T-cell lineage, is known to be deeply involved in the development of autoimmunity and allergy. TH17 cells have been shown to upregulate TH2 cell-mediated eosinophilic airway inflammation.<sup>21</sup>

### **THE IMPLICATION OF ATOPIC STATUS AND TH1-TH2 BALANCE**

There are documented allergic and immunologic factors associated with the development of ECRS. Several reports have intensively debated the role of nasal allergen sensitization in the development of ECRS in accordance with the increased incidence of an atopic population in recent years.<sup>22-25</sup> A role of IgE specific for enterotoxins from *Staphylococcus aureus*, which act as superantigens resulting in a multiclonal stimulation of T and B lymphocytes, has also been pro-

posed in the pathogenesis of ECRS.<sup>26</sup> Allergic status is considered a disorder of the entire respiratory tract rather than limited to a specific target organ. In this sense, the pathological features of chronic sinusitis in allergic subjects can be considered dependent on the effects of Th2 cytokines.<sup>27</sup> However, the original cause of eosinophil recruitment in ECRS remains controversial, and several authors have claimed that atopic status does not affect eosinophil infiltration in the disease.<sup>4,28</sup> It has been reported that neither total IgE concentrations nor ECP, IL-4, or IL-5 concentrations in eosinophilic nasal polyps are different in atopic versus nonatopic subjects, indicating a discordance between systemic allergic phenotype and local inflammatory mechanisms.<sup>1</sup> Jankovski *et al.* examined the degree of eosinophil infiltration in a series of 263 adult patients with nasal polyposis.<sup>4</sup> The number of eosinophils was increased in patients with asthma, although atopic patients did not have more eosinophils. Driscoll *et al.* also found the presence of significantly more CD4+ cells in the sinus mucosa of sinusitis patients than in the normal sphenoid sinus tissue, a finding that was not related to allergic status.<sup>29</sup> IFN- $\gamma$  is a well-known Th1 cytokine and its production is depressed in CD4-positive cells from atopic subjects. Jyonouchi *et al.* analyzed the production of proinflammatory cytokines by sinus lavage cells and proposed that distinguished subsets of sinusitis patients without nasal polyposis in Japan existed on the basis of local IFN- $\gamma$  production.<sup>30</sup>

Despite the bias toward the Th2 profile, many studies have demonstrated a mixed profile of Th1 and

Th2 cytokines in ECRS.<sup>17</sup> We performed immunohistological analysis of paranasal sinus mucosa in Japanese sinusitis patients ( $n = 132$ ).<sup>13</sup> Interestingly, the overall distribution of eosinophil density in all patients showed a combination of two different standardized shapes, indicating the coexistence of two different subgroups in the sinusitis pathology.<sup>14</sup> Local expression of a panel of cytokine mRNA and the distribution of CD4-, CXCR3-, and CCR4-positive cell subsets were quantitatively analyzed. Cells expressing CXCR3 and CCR5 have been associated with the Th1 cytokine profile, whereas CCR3, CCR4, and CCR 8 have been associated with the Th2 phenotype.<sup>31,32</sup> The ECRS group showed similar cytokine profiles with high expression levels for GM-CSF, IL-5, and eotaxin mRNA. The total number of CD4+ cells and the density of CCR4-positive CD4+ cells was significantly higher in this group, irrespective of the presence of AR. These findings point toward separate pathogenetic pathways in ECRS that induce prolonged inflammatory responses and interfere with normal mucociliary clearance.

### **POSSIBLE FACTORS RESPONSIBLE FOR EOSINOPHIL RECRUITMENT**

The exact reason for high eosinophil infiltration accompanied with a shift to a more type 2-dominated response in ECRS patients is still unclear. However, more than one mechanism seems to contribute to the responses.<sup>16</sup> Terada *et al.* mentioned that a hypoxic state in paranasal sinuses activated endothelial cells and fibroblasts to release inflammatory mediators, leading to promotion of the adherence of inflammatory cells to the endothelium. These include proinflammatory cytokines such as TNF- $\alpha$  and IFN- $\gamma$ , as well as Th2 cytokines, including IL-4 and IL-13, even in non atopic subjects.<sup>33</sup>

Recently, the role of innate immunity in the paranasal sinuses has been proposed.<sup>34</sup> It is well known that airway epithelial cells not only play an important role as the first line of immune defense, but also participate in adaptive and innate immune systems to maintain homeostasis and coordinate host defense.<sup>17,35,36</sup> Paranasal sinus epithelial cells can serve as antigen-presenting cells and amplify the inflammatory response at the local tissue level through an innate immunity. Airborne fungi, staphylococcal superantigens, bacterial biofilms, and viral infections have all been found to be potential triggers.

We previously observed constitutive activation of nuclear factor-kappa B (NF- $\kappa$ B), a transcription factor deeply implicated in the regulation of various inflammatory cytokines, in the nasal polyp epithelium.<sup>37</sup> NF- $\kappa$ B is a representative transcription factor that deals with the gene expression of several molecules related to various inflammatory states.<sup>38</sup> Various proinflammatory cytokines, chemokines, adhesion molecules, and inducible enzymes are activated

through the NF- $\kappa$ B pathway. A close correlation was found to exist between the degree of NF- $\kappa$ B activation and the levels of IL-8, IL-16, and eotaxin mRNA expression. We also found that the expression of NF- $\kappa$ B p50 and p65 subunits in cultured human paranasal sinus epithelial cells was upregulated in allergic patients compared to non-AR patients.<sup>39</sup> The increased NF- $\kappa$ B activity in the structural cells can thus be considered to reflect hypersensitivity to external stimuli, and to in part be responsible for eosinophil recruitment (Fig. 2).<sup>40</sup>

Several authors have demonstrated the significance of the innate immune response induced by toll-like receptors (TLRs) in the human paranasal sinus mucosa. Toll-like receptors are now recognized as being part of the innate immune system in the human airway.<sup>41,42</sup> The expression of TLRs in the paranasal sinus mucosa is thought to be dependent on the degree of each inflammation state and different from that in the nasal cavity.<sup>34</sup> In the nasal cavity, where microbial interaction is frequent, there is likely to be negative regulation of TLR activation and development of tolerance to normal upper flora. TLR1 to TLR 10 are expressed in sinus tissue and studies by real-time PCR suggest differences in the level of expression of TLRs in chronic rhinosinusitis as compared to normal controls.<sup>17</sup> Among them, TLR2 and TLR4 have been identified as signaling receptors activated by bacterial cell wall components. Dong *et al.* reported that TLR2 and TLR4 mRNA were significantly up-regulated in human nasal epithelial cells of the inferior turbinate under infectious conditions as measured by *in situ* hybridization.<sup>41</sup> It is, therefore, likely that pathogens, including TLRs ligands, may trigger an abnormal immune response at the mucosal surface.

We found that the NF- $\kappa$ B p50 activity levels, as measured using the Trans AM assay<sup>TM</sup>, increased after stimulation with lipopolysaccharide (LPS) and peptidoglycan (PGN) in a dose-dependent manner.<sup>43</sup> TLRs are known to activate the NF- $\kappa$ B pathway through MyD88, an IL-1 receptor-associated kinase, and TNF-associated factor-6. The stimulatory effects were significantly suppressed by pretreatment with dexamethasone (DEX). In addition, uniform expression of the GR protein in cultured cells was identified under all conditions and GR depletion from the cytoplasm induced by DEX pretreatment was associated with a corresponding increase in GR levels into the nucleus. These results indicate that external stimulation through TLRs may induce high cytokine expression and inflammatory cell migration in the paranasal sinus mucosa.<sup>35,41,42</sup> In addition, glucocorticoids (GCs) not only have anti-inflammatory effects through transcription factor inhibition, but also modulate innate host defenses. It was reported that the addition of DEX to a combination of TNF- $\alpha$  and IFN- $\gamma$  synergistically upregulated TLR2 expression in

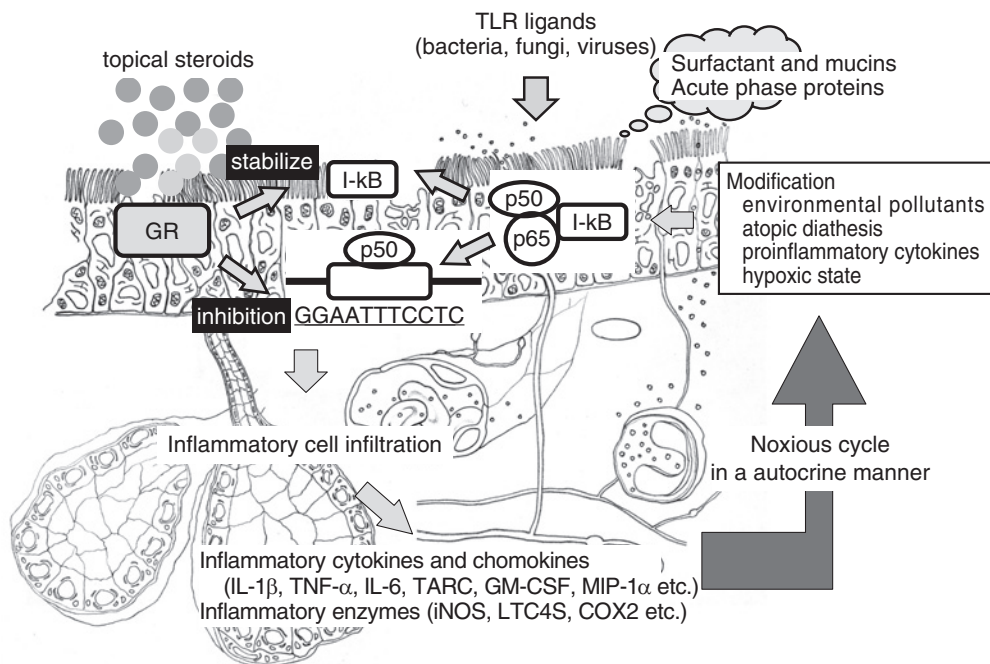


Fig. 2 Model of immune response in ECRS.

the cultured airway epithelial cells.<sup>44</sup> These multifunctional aspects of GC in paranasal sinus epithelial cells indicate that GCs are capable of not only anti-inflammatory effects via transcription factor inhibition, but also enhancement of the innate host defense.<sup>45</sup>

### CLINICAL TREATMENT MODALITIES OF ECRS

The phenotype of ECRS appears to affect prognosis after surgical or medical intervention. Haruna *et al.* reported that a significant increase in the eosinophil population was histologically observed in sinusitis patients whose therapeutic efficacy with long-term macrolide therapy was poor.<sup>46</sup> The objectives of management of ECRS include eradicating diseased mucosa and nasal polyps, eliminating subjective symptoms such as nasal obstruction, rhinorrhea and insomnia, and preventing recurrence. There are several treatment modalities such as the use of systemic/topical steroids, antileukotrienes and surgery.<sup>3</sup>

Figure 3 illustrates the treatment strategies proposed for ECRS patients directly aimed at local eosinophil infiltration. Surgical procedures include widely opening the bony wall septum of every affected sinus and mechanical removal of diseased mucosal lesion. The combination of septoplasty and submucosal inferior turbinectomy should also be considered in order to obtain easier accessibility for postsurgical follow-up. Medication should be focused on retrieval from impaired mucosal conditions caused by ongoing eosinophilic inflammation. The use of local

and/or systemic steroids, leukotriene receptor antagonists, and Th2 cytokine antagonists is recommended. Postsurgical local treatment on an outpatient basis such as nasal douching and nebulizer therapy is also important. In case of relapse of nasal polyps and deterioration of the mucosal condition triggered by acute respiratory infection, prompt intervention is necessary to avoid a noxious autocrine cycle of eosinophilic inflammation.

### LEUKOTRIENE RECEPTOR ANTAGONISTS

Leukotrienes are derivatives of arachidonic acid and induce a wide range of physiological reactions including bronchoconstriction, vasodilation, an increase in vascular permeability, eosinophil chemotaxis and mucus secretion. Several findings indicate that increased levels of CysLT receptors in persons with ECRS intensify eosinophilic inflammation in paranasal mucosa.<sup>47-49</sup> ECRS patients accompanied by aspirin intolerance asthma (AIA) are known to have greater cysteinyl leukotriene (CysLT) production.<sup>47</sup> In the AIA patients, the absolute number of cells expressing CysLT1 receptors was reported to be significantly higher as compared to that in non-AIA patients, whereas the percentage of CD45+ leukocytes expressing LTB4 receptors showed no difference.<sup>48</sup> In humans, mast cells, neutrophils, eosinophils, and macrophages positively express CysLT1 receptors,<sup>49</sup> indicating that autocrine and paracrine activation may occur after stimulation by the appropriate inflammatory signaling. Ragab *et al.* evaluated the efficiency of montelukast in patients with nasal polyps by nasal en-

Medical treatment effective for sinusitis caused by OMC disease  
= low-dose macrolides and mucolytic agents



Alternative treatment strategies directly aimed at local eosinophil infiltration

- 1) Surgical procedures (ESS)  
Widely open bony septum of every sinus and mechanically remove diseased mucosal area. Combination of septoplasty and submucosal inferior turbinectomy should be considered to obtain easier accessibility for postsurgical follow-up.
- 2) Medication  
Impairment of immune capabilities and normal clearance systems caused by ongoing eosinophilic inflammation should be considered.  
local and/or systemic steroids  
leukotriene receptor antagonists, Th2 cytokine antagonists
- 3) Postsurgical local treatment on outpatient basis  
Importance of continuous local treatment (nasal douching, nebulizer etc.).  
Prompt intervention against relapse of nasal polyps and deterioration of mucosal condition. Avoidance of noxious autocrine cycle of eosinophilic inflammation.

**Fig. 3** Current treatment strategies for ECRS.

doscopy, acoustic rhinometry, and subjective symptoms. Clinical improvement in the patients occurred in 64% of aspirin tolerant patients and in 50% of aspirin sensitive patients.<sup>50</sup> The beneficial efficacy of montelukast combined with short-term steroid therapy in nasal polyposis has also been reported.<sup>51</sup>

### **GLUCOCORTICOIDS**

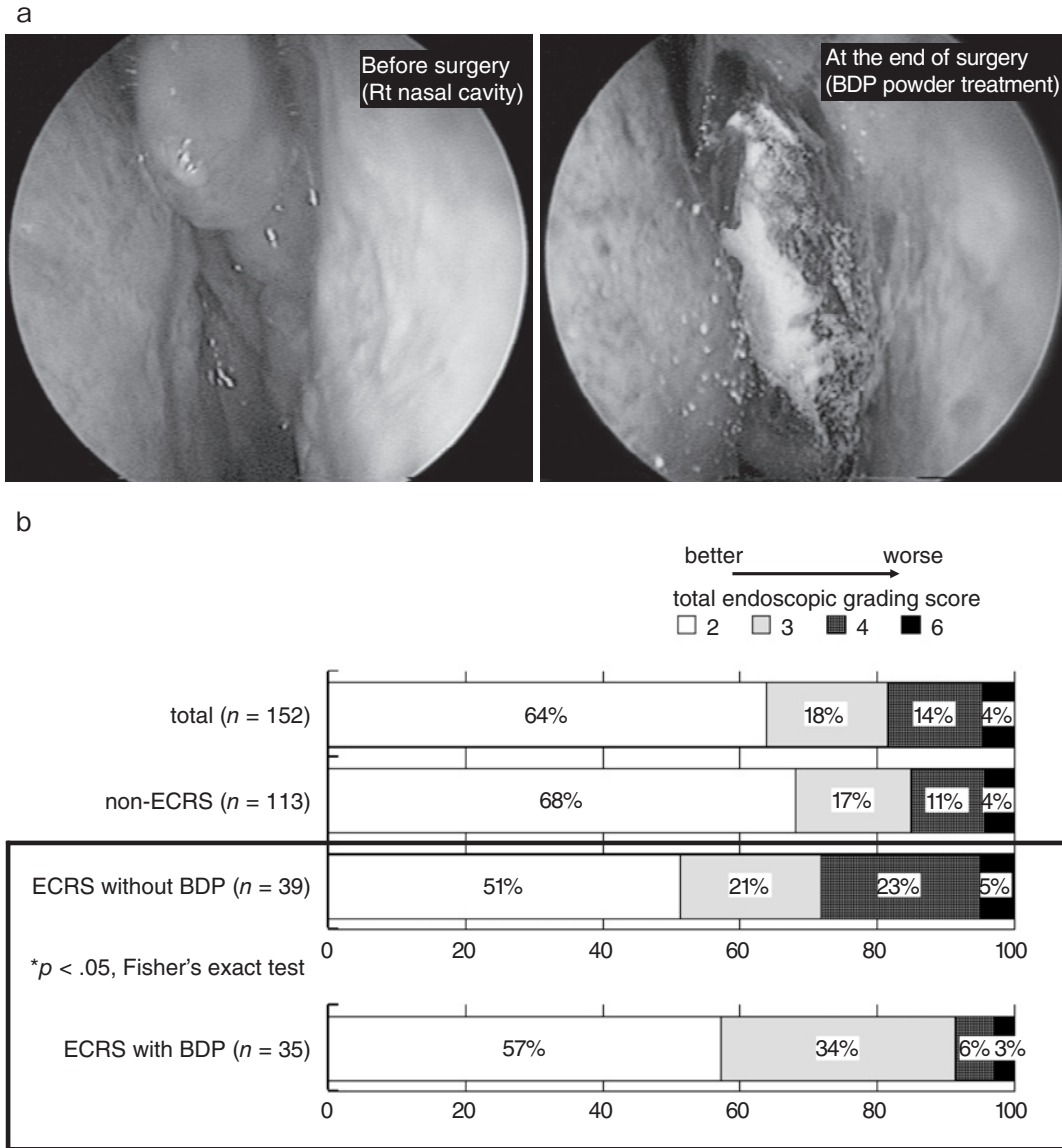
Glucocorticoids are known to have potent anti-inflammatory and anti-allergic effects based on their ability to regulate transcription factors that initiate gene activation of various inflammatory cytokines, adhesion molecules, and inflammatory mediators.<sup>52-54</sup> Glucocorticoid receptors (GRs) are widely expressed in various kinds of cells including epithelial cells and infiltrating cells located in the nose and paranasal sinuses. Therefore, the anti-inflammatory effect of GCs directly impacts the paranasal sinus mucosa. Relatively, higher levels of GR expression in ECRS patients suggests that glucocorticoids may exert a greater influence on eosinophils, thereby making them more effective in the treatment of the disease. A relationship between GR isoform patterns and the clinical effectiveness of steroid treatment has been reported in human nasal polyps.<sup>55</sup>

Resistance to steroid treatment is one of the major causes of clinical failure in the treatment of ECRS and thus an interesting topic of study.<sup>56,57</sup> Two isoforms of the human GR were identified in 1985 and termed GR $\alpha$  (GR $\alpha$ ) and GR $\beta$  (GR $\beta$ ), which originate from alternative splicing of the GR primary transcript. When overexpressed in various cell types, GR $\beta$  acts as a dominant-negative inhibitor of GR $\alpha$  for the repression of AP-1 and NF- $\kappa$ B activities.<sup>58</sup> The overexpression of GR $\beta$  has been shown to contribute to diseases associated with glucocorticoid resistance or insensitivity.<sup>56,57</sup>

We have examined immunohistochemical localization of different GR isoform expression in the paranasal sinus mucosa in ECRS patients. GR $\beta$  expression was mainly found to be positive in inflammatory cells that were scattered in the submucosal layer. It has been reported that nearly all of the GR $\beta$ -positive inflammatory cells were accounted for by CD3-positive T lymphocytes, activated eosinophils, and CD68-positive macrophages.<sup>57</sup> The finding tended to be more predominant in the ethmoid sinus mucosa than in the maxillary sinus mucosa in the same subject. Various proinflammatory cytokines have been reported to induce an increased expression of GR $\beta$  in vitro. The increased expression of GR $\beta$  in the inflammatory cells from ECRS patients could be in part secondary to the effect of high levels of those proinflammatory cytokines in a paracrine fashion.<sup>59</sup> In addition, a higher expression of GR $\beta$  in certain poor responders may also represent a secondary drug resistance mechanism in the disease.

Local administration of glucocorticoids is clinically considered to be a potent treatment strategy to prevent relapse of nasal polyposis in ECRS patients. The beneficial effects of various preparations of topical corticosteroids, such as betamethasone sodium phosphate, beclomethasone dipropionate, fluticasone propionate, mometasone furoate, and budesonide nasal sprays, have been demonstrated in several randomized, placebo-controlled trials.<sup>60,61</sup> With respect to bioavailability, systemic absorption is negligible with mometasone and fluticasone but high for betamethasone and dexamethasone, which should be used in the short-term.

Postoperative administration of intranasal corticosteroids has also been demonstrated to reduce nasal polyp recurrence and deterioration of the mucosal condition after endoscopic sinus surgery. However,



**Fig. 4** (a) A representative case of ECRS patients who had received topical use of BDP dry powder for the post-surgical treatment. (b) Postoperative assessment of endoscopic appearance of the nasal cavity in sinusitis patients after the ESS in Hiroshima University Hospital (modified from Takeno *et al.*, 2007). The total endoscopic grading score is calculated on the basis of the local grading scale for the maxillary and ethmoid sinuses on both sides.

there is no evidence for how long treatment would be appropriate.<sup>2</sup> We recently evaluated the clinical effectiveness of the topical instillation of beclomethasone dipropionate (BDP) dry powder onto the paranasal sinus mucosa after surgical intervention in ECRS patients.<sup>62</sup> The patients were treated with 800 µg BDP powder every two weeks using a special application device for at least 2 months (Fig. 4a). As shown in Figure 4b, distinct improvement in the endoscopic appearance scores occurred in 91.4% of patients who received BDP powder treatment. The result was bet-

ter than that obtained from the previous study in which treatment was done with conventional therapy (71.7%). Significant decreases in the averaged CT scores for the paranasal sinuses were also noted. We consider the BDP treatment to be effective for ECRS patients through the control of the inflammatory process that persists in the paranasal cavity.

The administration of systemic steroids is recommended in the short term and preferably in combination with use of a topical nasal steroid. A recent double-blind randomized controlled trial established

the clinical utility of a short course of oral prednisone in patients with nasal polyps.<sup>63</sup> Oral steroids used preoperatively in sinusitis patients with nasal polyps undergoing endoscopic sinus surgery have been shown to reduce bleeding volume and consequently improve conditions of the surgical field, leading to a shorter operating time.<sup>64</sup>

## SURGICAL TREATMENT

The beneficial outcomes of endoscopic sinus surgery have been well described in ECRS patients. Although it might be difficult to compare each technique and result from different groups, one key point is that surgical procedures alone are generally not sufficient to cure the underlying inflammatory processes of the nasal mucosa in ECRS patients.<sup>46</sup> As shown in Figure 3, supplementary medical treatment is usually necessary to prevent recurrence of the disease. The appearance of both an intra- and postoperative low number of eosinophils seems to be an indicator of good subjective recovery. Validation of the clinical, objective and immunological parameters that accompany recurrence of ECRS during the post-operative course indicate that long-term follow-up is essential for ECRS patients. The beneficial effect of ESS has recently been proposed to decrease eosinophil traffic into the maxillary sinus mucosa through the reduction of endothelial L-Selectin ligands.<sup>65</sup> Matsuwaki *et al.* reported that patients with ECRS showed a high incidence of recurrence within 5 years and had a positive predictive value of 85.7%.<sup>66</sup>

## CONCLUSION

We discussed the current understanding of basic and clinical aspects of ECRS among the Japanese population. Eosinophil accumulation in sinus tissue can be attributable to an autostimulatory loop of related cytokines and mediators, regardless of atopic status. The clinical efficacy of steroids in the management of ECRS has become apparent. The beneficial outcomes of ESS have also been described in combination with supplementary local treatment on an outpatient basis to prevent abrupt deterioration of the disease. Further accumulation of a consensus regarding the classification and definition of various subtypes of the disease might be required.

## REFERENCES

- Meltzer EO, Hamilos DL, Hadley JA *et al.* Rhinosinusitis: establishing definitions for clinical research and patient care. *J Allergy Clin Immunol* 2004;**114**(6 Suppl):155-212.
- Scadding GK, Durham SR, Mirakianz R *et al.* BSACI guidelines for the management of rhinosinusitis and nasal polyposis. *Clin Exp Allergy* 2007;**38**:260-75.
- Fokkens W, Lund V, Mullol J; European Position Paper on Rhinosinusitis and Nasal Polyps group. European position paper on rhinosinusitis and nasal polyps 2007. *Rhinol Suppl* 2007;**20**:1-136.
- Jankowski R, Bouchoua F, Coffinet L, Vignaud JM. Clini-

- cal factors influencing the eosinophil infiltration of nasal polyps. *Rhinology* 2002;**40**:173-8.
- Demoly P, Crampette L, Mondain M *et al.* Assessment of inflammation in noninfectious chronic maxillary sinusitis. *J Allergy Clin Immunol* 1994;**94**:95-108.
- Hamilos DL. Chronic sinusitis. *J Allergy Clin Immunol* 2000;**106**:213-27.
- Danese M, Duvoisin B, Agrifoglio A, Cherpillod J, Krayenbuhl M. [Influence of naso-sinusal anatomic variants on recurrent, persistent or chronic sinusitis. X-ray computed tomographic evaluation in 112 patients]. *J Radiol* 1997;**78**:651-7 (in French).
- Hoover GE, Newman LJ, Platts-Mills TA, Phillips CD, Gross CW, Wheatley LM. Chronic sinusitis: risk factors for extensive disease. *J Allergy Clin Immunol* 1997;**100**:185-91.
- Watelet JB, Demetter P, Claeys C *et al.* Wound healing after paranasal sinus surgery: neutrophilic inflammation influences the outcome. *Histopathology* 2006;**48**:174-81.
- Zadeh MH, Banthia V, Anand VK *et al.* Significance of eosinophilia in chronic rhinosinusitis. *Am J Rhinol* 2002;**16**:313-7.
- Haruna S, Otori N, Moriyama H *et al.* Olfactory dysfunction in sinusitis with infiltration of numerous activated eosinophils. *Auris Nasus Larynx* 2006;**33**:23-30.
- Szucs E, Ravandi S, Goossens A *et al.* Eosinophilia in the ethmoid mucosa and its relationship to the severity of inflammation in chronic rhinosinusitis. *Am J Rhinol* 2002;**16**:131-4.
- Takeno S, Yajin K, Hisayuki A *et al.* Comparison of local cytokine gene expression and the distribution of eosinophils and CD4-positive cell subsets in the paranasal sinus mucosa between atopic and non atopic subjects. *Allergol Int* 2004;**53**:135-44.
- Berger G, Kattan A, Bernheim J, Ophir D. Polypoid mucosa with eosinophilia and glandular hyperplasia in chronic sinusitis: a histopathological and immunohistochemical study. *Laryngoscope* 2002;**112**:738-45.
- Gleich GJ. Mechanisms of eosinophil-associated inflammation. *J Allergy Clin Immunol* 2000;**105**:651-63.
- Ponikau JU, Sherris DA, Kephart GM *et al.* Striking deposition of toxic eosinophil major basic protein in mucus: Implications for chronic rhinosinusitis. *J Allergy Clin Immunol* 2005;**116**:362-9.
- Shleimer RP, Lane AP, Kim J. Innate and acquired immunity and epithelial cell function in chronic rhinosinusitis. *Clin Allergy Immunol* 2007;**20**:51-78.
- Yao T, Kojima Y, Koyanagi A *et al.* Eotaxin-1, -2, and -3 immunoreactivity and protein concentration in the nasal polyps of eosinophilic chronic rhinosinusitis patients. *Laryngoscope* 2009;**119**:1053-9.
- Cao PP, Li HB, Wang BF *et al.* Distinct immunopathologic characteristics of various types of chronic rhinosinusitis in adult Chinese. *J Allergy Clin Immunol* 2009;**124**:478-84.
- Kim JW, Hong SL, Kim YK, Lee CH, Min YG, Rhee CS. Histological and immunological features of non-eosinophilic nasal polyps. *Otolaryngol Head Neck Surg* 2007;**137**:925-30.
- Wakashin H, Hirose K, Maezawa Y *et al.* IL-23 and Th17 cells enhance Th2 cell-mediated eosinophilic airway inflammation in mice. *Am J Respir Crit Care Med* 2008;**178**:1023-32.
- Kamil A, Graffer O, Lavigne F, Taha R, Renzi PM, Hamid Q. Comparison of inflammatory cell profile and Th2 cytokine expression in the ethmoid sinus, maxillary sinus,



- and turbinate of atopic subjects with chronic sinusitis. *Otolaryngol Head Neck Surg* 1998;**118**:804-9.
23. Ramadan HH, Fornelli R, Ortiz AO, Rodman S. Correlation of allergy and severity of sinus disease. *Am J Rhinol* 1999;**13**:345-7.
  24. Emanuel IA, Shah SB. Chronic rhinosinusitis: allergy and sinus computed tomography relationships. *Otolaryngol Head Neck Surg* 2000;**123**:687-91.
  25. Mucha SM, Baroody FM. Sinusitis update. *Curr Opin Allergy Clin Immunol* 2003;**3**:33-8.
  26. Bachert C, Gevaert P, Holtappels G, Johansson SG, van Cauwenberge P. Total and specific IgE in nasal polyps is related to local eosinophilic inflammation. *J Allergy Clin Immunol* 2001;**107**:607-14.
  27. Christodouloupoulos P, Cameron L, Durham S, Hamid Q. Molecular pathology of allergic disease. II: Upper airway disease. *J Allergy Clin Immunol* 2000;**105**:211-23.
  28. Elwany S, Bassyouni M, Morad F. Some risk factors for refractory chronic sinusitis: an immunohistochemical and electron microscopic study. *J Laryngol Otol* 2002;**116**:112-5.
  29. Driscoll PV, Naclerio RM, Baroody FM. CD4+ lymphocytes are increased in the sinus mucosa of children with chronic sinusitis. *Arch Otolaryngol Head Neck Surg* 1996;**122**:1071-6.
  30. Jyonouchi H, Sun S, Kelly A, Rimell FL. Effects of exogenous interferon gamma on patients with treatment-resistant chronic rhinosinusitis and dysregulated interferon gamma production: a pilot study. *Arch Otolaryngol Head Neck Surg* 2003;**129**:563-9.
  31. Qin S, Rottman JB, Myers P *et al.* The chemokine receptors CXCR3 and CCR5 mark subsets of T cells associated with certain inflammatory reactions. *J Clin Invest* 1998;**101**:746-54.
  32. Imai T, Nagira M, Takagi S *et al.* Selective recruitment of CCR4-bearing Th2 cells toward antigen-presenting cells by the CC chemokines thymus and activation-regulated chemokine and macrophage-derived chemokine. *Int Immunol* 1999;**11**:81-8.
  33. Terada N, Gorai S, Jeong KW, Nomura T, Numata T, Konno A. Mechanisms of eosinophilic inflammation in the mucosa of the nasal cavity and paranasal sinus. *Allergol Int* 2001;**50**:171-7.
  34. Ooi EH, Wormald PJ, Tan LW. Innate immunity in the paranasal sinuses: a review of nasal host defenses. *Am J Rhinol* 2008;**22**:13-9.
  35. Lane AP, Truong-Tran QA, Schleimer RP. Altered expression of genes associated with innate immunity and inflammation in recalcitrant rhinosinusitis with polyps. *Am J Rhinol* 2006;**20**:138-44.
  36. Sachse F, von Eiff C, Stoll W, Becker K, Rudack C. Induction of CXC chemokines in A549 airway epithelial cells by trypsin and staphylococcal proteases—a possible route for neutrophilic inflammation in chronic rhinosinusitis. *Clin Exp Immunol* 2006;**144**:534-42.
  37. Takeno S, Hirakawa K, Ueda T, Furukido K, Osada R, Yajin K. Nuclear factor-kappa B activation in the nasal polyp epithelium: Relationship to local cytokine gene expression. *Laryngoscope* 2002;**112**:53-8.
  38. Harada K, Isse K, Nakamura Y. Interferon gamma accelerates NF-kappa B activation of biliary epithelial induced by Toll-like receptor and ligand interaction. *J Clin Pathol* 2006;**59**:184-90.
  39. Osada R, Takeno S, Hirakawa K *et al.* Expression and localization of nuclear factor-kappa B subunits in cultured human paranasal sinus mucosal cells. *Rhinology* 2003;**41**:80-6.
  40. Ramis I, Bioque G, Lorente J *et al.* Constitutive nuclear factor- $\kappa$ B activity in human upper airway tissue and nasal epithelial cells. *Eur Respir J* 2000;**15**:582-9.
  41. Dong Z, Yang Z, Wang C. Expression of TLR2 and TLR4 messenger RNA in the epithelial cells of the nasal airway. *Am J Rhinol* 2005;**19**:236-9.
  42. Lane AP, Truong-Tran QA, Myers A, Bickel C, Schleimer RP. Serum amyloid A, properdin, complement 3, and toll-like receptors are expressed locally in human sinonasal tissue. *Am J Rhinol* 2006;**20**:117-23.
  43. Nishi Y, Takeno S, Ishino T, Hirakawa K. Glucocorticoids suppress NF- $\kappa$ B activation induced by LPS and PGN in paranasal sinus epithelial cells. *Rhinology* 2009;**47**:413-8.
  44. Homma T, Kato A, Hashimoto N *et al.* Corticosteroid and cytokines synergistically enhance toll-Like receptor 2 expression in respiratory epithelial cells. *Am J Respir Cell Mol Biol* 2004;**31**:463-9.
  45. Chinenov Y, Rogatsky I. Glucocorticoids and the innate immune system: Crosstalk with the toll-like receptor signaling network. *Mol Cell Endocrinol* 2007;**275**:30-42.
  46. Haruna S, Shimada C, Ozawa M, Fukami S, Moriyama H. A study of poor responders for long-term, low-dose macrolide administration for chronic sinusitis. *Rhinology* 2009;**47**:66-71.
  47. Steinke JW, Bradley D, Arango P. Cysteinyl leukotriene expression in chronic hyperplastic sinusitis-nasal polyposis: Importance to eosinophilia and asthma. *J Allergy Clin Immunol* 2003;**112**:342-9.
  48. Sousa AR, Parikh A, Scadding G, Corrigan CJ, Lee TH. Leukotriene-receptor expression on nasal mucosal inflammatory cells in aspirin-sensitive rhinosinusitis. *N Engl J Med* 2002;**347**:1493-9.
  49. Shirasaki H, Kanaizumi E, Watanabe K *et al.* Expression and localization of the cysteinyl leukotriene 1 receptor in human nasal mucosa. *Clin Exp Allergy* 2002;**32**:1007-12.
  50. Ragab S, Parikh A, Darby YC, Scadding GK. An open audit of montelukast, a leukotriene receptor antagonist, in nasal polyposis associated with asthma. *Clin Exp Allergy* 2001;**31**:1385-91.
  51. Kütting B, Nieschalk M, Brehler R. A new concept for treatment of sinonasal polyposis. *Allergy* 2000;**55**:1091-2.
  52. Angeli A, Masera RG, Sartori ML *et al.* Modulation by cytokines of glucocorticoid action. *Ann N Y Acad Sci* 1999;**876**:210-20.
  53. Göttlicher M, Heck S, Herrlich P. Transcriptional cross-talk, the second mode of steroid hormone receptor action. *J Mol Med* 1998;**76**:480-9.
  54. Derendorf H, Meltzer EO. Molecular and clinical pharmacology of intranasal corticosteroids: clinical and therapeutic implications. *Allergy* 2008;**63**:1292-300.
  55. Choi BR, Kwon JH, Gong SJ *et al.* Expression of glucocorticoid receptor mRNA in glucocorticoid-resistant nasal polyps. *Exp Mol Med* 2006;**38**:466-73.
  56. Pujols L, Mullol J, Benítez P *et al.* Expression of the glucocorticoid receptor alpha and beta isoforms in human nasal mucosa and polyp epithelial cells. *Respir Med* 2003;**97**:90-6.
  57. Hamilos DL, Leung DYM, Muro S *et al.* GR $\beta$  expression in nasal polyp inflammatory cells and its relationship to the anti-inflammatory effects of intranasal fluticasone. *J Allergy Clin Immunol* 2001;**108**:59-68.
  58. Gougat C, Jaffuel D, Gagliardo R *et al.* Overexpression of the human glucocorticoid receptor alpha and beta isoforms inhibits AP-1 and NF- $\kappa$ B activities hormone independently. *J Mol Med* 2002;**80**:309-18.

59. Valera FC, Queiroz R, Scrideli C *et al.* Evaluating budesonide efficacy in nasal polyposis and predicting the resistance to treatment. *Clin Exp Allergy* 2009;**39**:81-8.
60. Small CB, Hernandez J, Reyes A *et al.* Efficacy and safety of mometasone furoate nasal spray in nasal polyposis. *J Allergy Clin Immunol* 2005;**116**:1275-81.
61. Stjarne P, Mosges R, Jorissen M *et al.* A randomized controlled trial of mometasone furoate nasal spray for the treatment of nasal polyposis. *Arch Otolaryngol Head Neck Surg* 2006;**132**:179-85.
62. Take no S, Takeda K, Nishi Y, Ishino T, Hirakawa K. Clinical effectiveness of local application of beclomethasone dipropionate dry powder for the treatment of chronic rhinosinusitis with eosinophil infiltration. *Nihon Bika Gakkai Kaishi [Jpn J Rhinol]* 2007;**46**:102-8 (in Japanese).
63. Hissaria P, Smith W, Wormald PJ *et al.* Short course of systemic corticosteroids in sinonasal polyposis: a double-blind, randomized, placebocontrolled trial with evaluation of outcome measures. *J Allergy Clin Immunol* 2006;**118**:128-33.
64. Sieskiewicz A, Olszewska E, Rogowski M, Grycz E. Pre-operative corticosteroid oral therapy and intraoperative bleeding during functional endoscopic sinus surgery in patients with severe nasal polyposis: a preliminary investigation. *Ann Otol Rhinol Laryngol* 2006;**115**:490-4.
65. Myller JP, Toppila-Salmi SK, Toppila EM *et al.* Mucosal eosinophils and I-selectin ligands are associated with invasive and noninvasive sinus surgery outcomes. *Am J Rhinol Allergy* 2009;**23**:21-7.
66. Matsuwaki Y, Ookushi T, Asaka D *et al.* Chronic rhinosinusitis: risk factors for the recurrence of chronic rhinosinusitis based on 5-year follow-up after endoscopic sinus surgery. *Int Arch Allergy Immunol* 2008;**146** (Suppl 1):77-81.