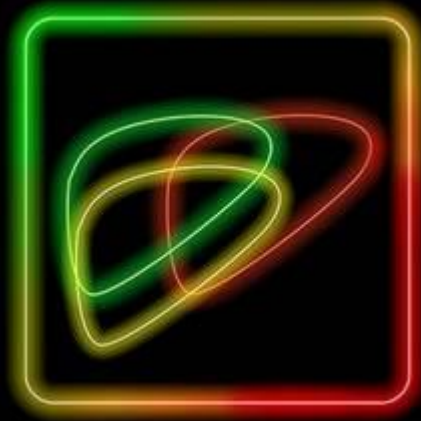
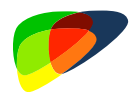



American College
of Radiology™

LI-RADS® CEUS Nonradiation TRA v2024 Manual





LI-RADS® CEUS NONRADIATION TRA v2024

Observation treated by nonradiation-based Locoregional Therapy (TACE, TAE, RFA, MWA or PEA), or at surgical margin after resection, imaged with CEUS in at-risk patient.

Step 1. Assess both intralesional AND perilesional tumor viability using CEUS Imaging Criteria. If not evaluable, assign LR-TR Nonevaluable and proceed to Step 4.

Intralesional Tumor Viability	CEUS Imaging Criteria	Perilesional Tumor Viability	CEUS Imaging Criteria
Absent	No intralesional enhancement	Absent	Enhancement identical to surrounding liver
Uncertain	Arterial phase hypoenhancement (with or without washout)	Uncertain	Arterial phase hyperenhancement without washout OR Arterial phase isoenhancement with washout OR Arterial phase hypoenhancement
Present	Arterial phase hyperenhancement (with or without washout) OR Arterial phase isoenhancement (with or without washout)	Present	Arterial phase hyperenhancement with washout

Step 2. Apply Tiebreaking Rule if needed

Step 3. Reconcile intralesional AND perilesional tumor viability assessment to assign a single Treatment Response Assessment (TRA) category

		<u>Intralesional Tumor Viability</u>		
		Absent	Uncertain	Present
<u>Perilesional Tumor Viability</u>	Absent	LR-TR Nonviable	LR-TR Equivocal	LR-TR Viable
	Uncertain	LR-TR Equivocal	LR-TR Equivocal	LR-TR Viable
	Present	LR-TR Viable	LR-TR Viable	LR-TR Viable

Step 4. Final check.

After steps 1, 2, and 3 – Ask yourself if the assigned TRA category is reasonable and appropriate.

If YES: You are done, move on to the next Treated Lesion (if any).

If NO: Re-evaluate.



- New distinct nodule(s) separate from Treated Lesion should be categorized using CEUS Diagnostic Algorithm instead of CEUS TRA Algorithm.
- In patients after partial hepatectomy the entire resection margin should be evaluated using Perilesional Tumor Viability criteria. In patients without surgical cavity visible on B-mode ultrasound Intralesional Tumor Viability should be labeled as “Absent”.



Table of Contents

	Pages
Overview	What is LI-RADS® Treatment Response Assessment? 1
	LI-RADS® Algorithms 2
	LI-RADS® Diagnostic and TRA Algorithms: Which to Use 3
Getting Started 4	
LI-RADS® Treatment Response Categories at a Glance 5	
Key Concepts 6	
Decision tree layout 9	
CEUS Nonradiation TRA algorithm	Step 1. Assess both intralesional AND perilesional tumor viability using CEUS Imaging Criteria 10
	Step 2. Apply Tiebreaking Rules if Needed 11
	Step 3. Reconcile Intralesional AND Perilesional tumor viability assessment to assign a single TRA category 12
	Step 4. Final check 12
Technique	Technical recommendations for CEUS Nonradiation TRA imaging 13
	Lexicon 15
	Limitations 16
Management 17	Suggested imaging workup options and time intervals
Reporting	Considerations before issuing a LI-RADS report in patients with lesions treated by LRT 18
	Reporting 19
	Reporting template 20



Table of Contents

	Pages
Definitions	Intralesional Tumor Viability Absent 21
	Intralesional Tumor Viability Uncertain 23
	Intralesional Tumor Viability Present 25
	Perilesional Tumor Viability Absent 27
	Perilesional Tumor Viability Uncertain 29
	Perilesional Tumor Viability Present 34
Posttreatment imaging after Nonradiation LRT 36	
FAQs	Getting Started 38
	Management 42
	Treated biopsy proven HCC in LR-3 and LR-4 43
	Treated LR-M, Cholangiocarcinoma, Combined Tumor 44
	Surgical Resection 45
Abbreviations 46	
Authors 47	
Acknowledgements 48	



What is LI-RADS® CEUS Treatment Response Assessment?

LI-RADS CEUS Treatment Response Assessment (TRA) is:

- A comprehensive system for standardizing Contrast-Enhanced Ultrasound (CEUS) acquisition, interpretation, reporting, and data collection for HCC and select cases of non-HCC malignancies (iCCA and cHCC-CCA), treated with locoregional therapy (LRT) or surgical resection.
- A dynamic document, to be expanded and refined as knowledge accrues and in response to user feedback.
- Designed to improve communication, patient care, education, and research.
- Supported and endorsed by the American College of Radiology (ACR).
- Developed by a multidisciplinary, international consortium of diagnostic and interventional radiologists, hepatobiliary surgeons, hepatologists, hepatopathologists, and radiation oncologists through literature review and expert consensus. Contributors include academic and community physicians as well as members in training.
- Complementary to other LI-RADS algorithms including LI-RADS CT/MRI TRA.

LI-RADS CEUS TRA may be used for clinical care, education, or research by:

- Community and academic radiologists
- Radiologists in training
- Other health care professionals providing care to patients with liver disease
- Researchers

Why is LI-RADS CEUS TRA important?

- Enables clear communication between radiologists and other specialists caring for patients after locoregional therapy and surgical resection.
- Provides standardized terminology to facilitate data collection, quality assurance, and research.
- Provides a simple, practical system suitable for routine clinical practice for assessing treatment response in individual lesions. This is particularly relevant in patients with liver-limited disease and to inform patient management including the need for retreatment.
- Prior systems (see below) were developed for clinical trials, emphasize overall patient response, and do not provide lesion-level treatment response assessment for each treated observation.

What are other treatment response systems?

- Response Evaluation Criteria in Solid Tumors (RECIST), modified RECIST (mRECIST), and European Association for the Study of Liver Disease (EASL) provide criteria to assess overall patient response in clinical trials and retrospective studies assessing treatment response for HCC patients, rather than to assess individual tumors or to inform clinical management.
- LI-RADS CT/MRI TRA uses concepts from mRECIST for assessment of viability and tumor size measurements following treatment. It uses imaging criteria of tumor viability different from LI-RADS CEUS TRA.



LI-RADS® Algorithms



US Surveillance
Algorithm

For **surveillance** of HCC

In **cirrhotic and other high-risk** patients

Using **unenhanced ultrasound**

Note: in some patients with VIS-C, alternative modalities such as CT or abbreviated MRI should be considered.



CEUS Diagnostic
Algorithm

For **diagnosis** of HCC and

Categorization of **new distinct nodule(s) separate from Treated Lesion** In **cirrhotic and other high-risk** patients

Using **contrast-enhanced ultrasound (CEUS)**



CT/MRI Diagnostic
Algorithm

For **diagnosis and staging** of HCC

In **cirrhotic and other high-risk** patients, including liver transplant candidates with HCC

Using **CT, MRI with extracellular agents (ECA), or MRI with hepatobiliary agents (HBA)**



CEUS Nonradiation TRA
Algorithm

For **assessing response to nonradiation-based LRT, including resection**, of HCC and select cases of non-HCC malignancies (iCCA and cHCC-CCA)

In **cirrhotic and other high-risk** patients, including liver transplant candidates with HCC

Using **CEUS**



CT/MRI Nonradiation TRA
Algorithm

For **assessing response to nonradiation-based LRT, including resection**, of any treated lesion, including HCC and other malignancies

In **cirrhotic and other high-risk** patients, including liver transplant candidates with HCC

Using **CT, MRI with ECA, or MRI with HBA**



CT/MRI Radiation TRA
Algorithm

For **assessing response to radiation-based LRT** of any treated lesion, including HCC and other malignancies

In **cirrhotic and other high-risk** patients, including liver transplant candidates with HCC

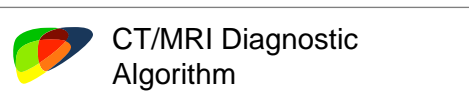
Using **CT, MRI with ECA, or MRI with HBA**



LI-RADS® Diagnostic and TRA Algorithms: Which to Use

Pretreatment

Untreated observation imaged by multiphase CT, MRI, or CEUS



CT/MRI Diagnostic Algorithm

Posttreatment

if treated

Treated observation imaged by multiphase CT, MRI, or CEUS

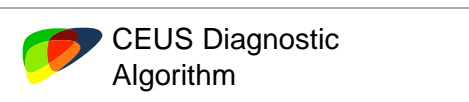
Systemic therapy

Assess treatment response with institutional or RECIST-type approach

Surgical resection: observation NOT at surgical margin

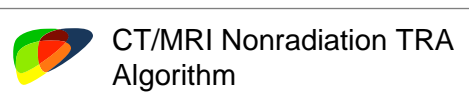


CT/MRI Diagnostic Algorithm

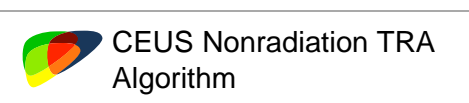


CEUS Diagnostic Algorithm

Surgical resection: observation at surgical margin

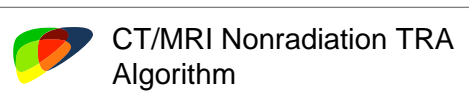


CT/MRI Nonradiation TRA Algorithm

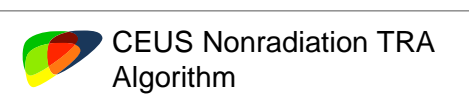


CEUS Nonradiation TRA Algorithm

Locoregional therapy with nonradiation-based treatment (ablation, TAE, cTACE, DEB-TACE)



CT/MRI Nonradiation TRA Algorithm



CEUS Nonradiation TRA Algorithm

Locoregional therapy with radiation-based treatment (TARE, SBRT)



CT/MRI Radiation TRA Algorithm



LI-RADS® CEUS NONRADIATION TRA v2024



Apply in high-risk patients to assess response for path-proven or presumed (LR-3, LR-4, LR-5, LR-M) HCC after locoregional treatment including surgical resection

High-risk patients are those with cirrhosis **OR** Chronic hepatitis B viral infection even in absence of cirrhosis **OR** current or prior HCC, including adult liver transplant candidates and recipients of liver transplant.



Apply to treated lesions imaged with contrast-enhanced ultrasound.



Apply nonradiation TRA algorithm after nonradiation-based LRT:

- Radiofrequency ablation (RFA)
- Microwave ablation (MWA)
- Percutaneous ethanol ablation (PEA)
- Transarterial embolization (TAE)
- Conventional transarterial chemoembolization (cTACE)
- Drug-eluting bead transarterial chemoembolization (DEB-TACE)



Apply to Treated Lesions:

- Visible on post-treatment B-mode ultrasound



Apply in postsurgical patients when assessing recurrence at the surgical margin, when surgical cavity or surgical margin is visible on ultrasound.



Apply with caution in select cases of non-HCC malignancies, such as iCCA and cHCC-CCA.



Do NOT apply in patients with Treated Lesion not visible on B-mode ultrasound.



Do NOT apply in new or untreated lesions outside treatment zone.



Do NOT apply in patients treated with radiation-based therapies or in patients on systemic therapy.



LI-RADS® CEUS NONRADIATION TRA v2024 Categories

CEUS Nonradiation TRA Algorithm Categories

LR-TR Nonevaluable

Treated by nonradiation-based therapy,
Response not evaluable due to image omission or degradation

LR-TR Nonviable

Treated by nonradiation-based therapy,
Probably or definitely not viable

LR-TR Equivocal

Treated by nonradiation-based therapy,
Equivocally viable

LR-TR Viable

Treated by nonradiation-based therapy,
Probably or definitely viable



Key Concepts

CEUS Nonradiation TRA

Tumor response to ablation and nonradiation-based intra-arterial embolization

Ablation and nonradiation-based intra-arterial embolization cause both tumor death and reactive changes in surrounding liver parenchyma. Surgical resection can produce reactive and granulation tissue development at the resection site. Hence, enhancement in treated lesion and along its margin might have different enhancement patterns, especially within first 4 weeks after treatment.

- Due to extremely high sensitivity of CEUS to vascular flow, post-treatment reactive changes are common and may manifest as areas of abnormal perilesional enhancement, especially during the first 3 months after treatment.
- **Treated Lesions:**
 - Treated lesions typically demonstrate no intralesional enhancement after successful treatment.
 - Arterial phase hyperenhancement or isoenhancement (with or without washout) within the Treated Lesion indicate persistent tumor viability.
 - Arterial phase hypoenhancement (with or without washout) within the Treated Lesion could be observed in incompletely treated lesions, but also in reactive/granulation tissue replacing successfully treated lesion.
- **Perilesional liver parenchyma:**
 - Locoregional treatments, especially percutaneous ablation, can lead to development of substantial hyperemia around the ablated area, typically seen within 1 month after treatment. This can result in false-positive cases by misdiagnosing the hyperenhancement along the borders of treatment cavity, as viable tumor as well as false-negative cases by failure to distinguish post-procedure inflammation from a true residual viable tumor.
 - Liver parenchyma surrounding Treated Lesion expected to return to normal enhancement after successful treatment within 3 months after treatment.
 - Abnormal enhancement in liver parenchyma surrounding Treated Lesion that persist for >6 month is concerning and should be further evaluated with an alternative imaging modality

Surgical resection

The appearance of Treated Lesion depends on the amount of surgically removed liver

- In patients after focal segmental or wedge resection it is common to see a surgical cavity or surface defect on B-mode ultrasound, which might appear “mass-like”. Tumor viability in this area should be evaluated using [Intralesional Tumor Viability](#) criteria. It should demonstrate no internal enhancement in patients with no viable disease.
- In patients after partial hepatectomy the entire resection margin is considered perilesional tissue and should be evaluated using [Perilesional Tumor Viability](#) criteria.
- In patients without surgical cavity visible on B-mode ultrasound [Intralesional Tumor Viability](#) should be labeled as “Absent”.



Tumor Viability Assessment:

- To improve the accuracy of CEUS for treatment response assessment, different diagnostic criteria are used to evaluate for disease viability within and outside of the Treated Lesion margins:
- Broader criteria for intralesional enhancement are used to increase sensitivity of tumor viability detection.
- Stricter criteria are used for perilesional enhancement to prevent misclassification of post-treatment reactive changes as viable tumor.

CEUS Nonradiation TRA reconciles intralesional and perilesional tumor viability assessment and assigns a single treatment response category:

- LR TR-Nonviable
- LR TR-Equivocal
- LR TR-Viable

Patients with treated lesion(s) categorized as LR-TR Viable and select cases with LR-Equivocal categorization should be reviewed at MDD for consensus management.

- **Concept:** the determination to retreat viable tumor or to change treatment is not based solely on the LR-TR category but is multifactorial.
- **Rationale:** Multiple factors are relevant in determining whether to retreat or change treatment, These include
 - patient's personal preferences, family and social circumstances, overall health
 - size, location, and number of viable tumors
 - size, location, number, and LI-RADS category of untreated observations
 - presence of extrahepatic metastases
 - prior treatment history
 - liver function
 - transplant eligibility
- In general, no single physician or specialist, including the radiologist assessing treatment response, will know all this relevant information.
- **Implications:**
 - The decision to retreat viable tumor or to change treatment is best made via a holistic approach that considers the above factors through multidisciplinary discussion (MDD).
 - Diagnostic radiologists should avoid language in their reports that compels treatment or change in treatment.



Treated Lesion

Intralesional vs. Perilesional contrast enhancement

Treated Lesion

After catheter-based treatments (TAE, cTACE, DEB-TACE):

- Treated observation visible on B-mode US

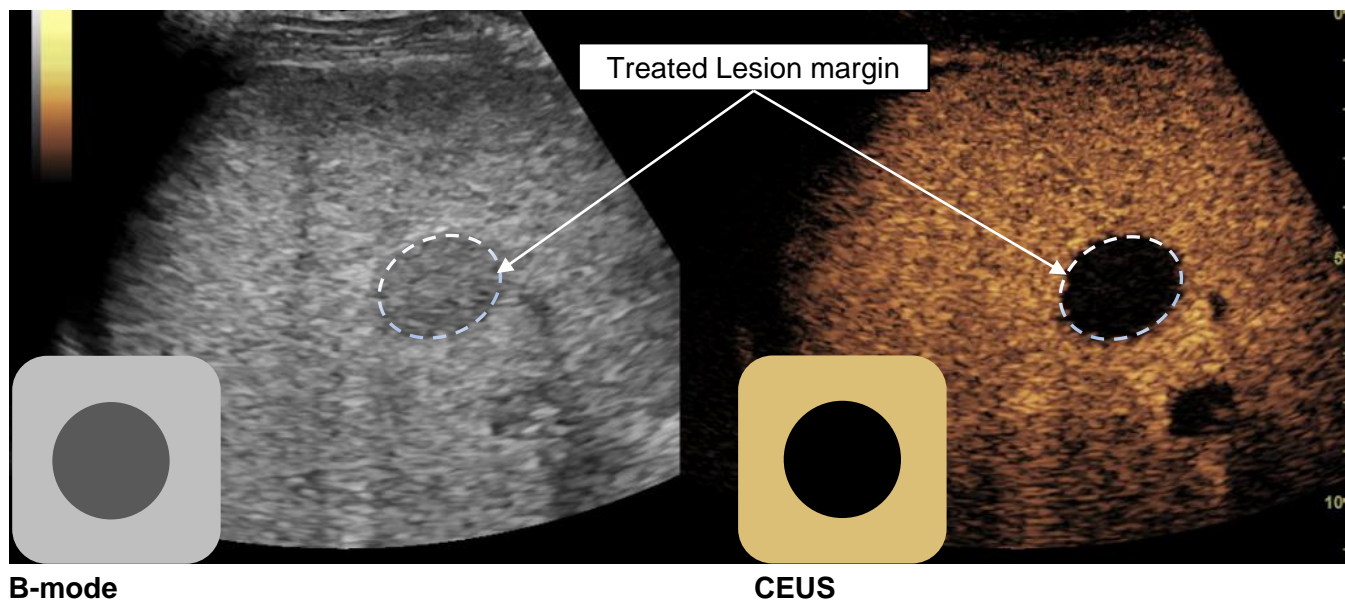
After percutaneous treatments (RFA, MWA, PEA):

- Combination of observation and parenchymal changes related to ablation procedure visible on B-mode US

After surgical resection:

- Surgical cavity after segmental or wedge resection visible on B-mode US

- CEUS LI-RADS Treatment Response Assessment leverages the unique ability of CEUS to visualize both anatomical (B-mode) and contrast-enhanced ultrasound images simultaneously and in real time.
- Using B-mode images as anatomical reference allows separate evaluation of contrast enhancement patterns inside and outside of the Treated Lesion.





LI-RADS® CEUS NONRADIATION TRA v2024 ALGORITHM

Treated Lesion OR margin of surgical resection visible on B-mode ultrasound

CEUS examination is technically adequate?

Adequate

Not adequate

Treatment response cannot be evaluated due to image degradation or omission

LR-TR Nonevaluable

Define margins of Treated Lesion on B-mode US

Assess both [intralesional](#) AND [perilesional](#) tumor viability on CEUS

Use [intralesional tumor viability table](#)

Use [perilesional tumor viability table](#)

Apply [Tiebreaking Rule](#) if needed

Apply [Tiebreaking Rule](#) if needed

[Reconcile intralesional AND perilesional](#) tumor viability

LR-TR Nonviable

LR-TR Equivocal

LR-TR Viable

New distinct nodule(s) separate from Treated Lesion, visible on ultrasound



CEUS Diagnostic Algorithm



Step 1.

Assess both intralesional AND perilesional tumor viability using CEUS Imaging Criteria

If not evaluable, assign LR-TR Nonevaluable and proceed to Step 4.

Intralesional Tumor Viability

	Conceptual definition	CEUS Imaging Criteria
Absent	Low or negligible likelihood of viable tumor within the margins of the Treated Lesion	No intralesional enhancement
Uncertain	The presence and the absence of viable tumor within the margins of Treated Lesion each have similar probability	Arterial phase hypoenhancement (with or without washout)
Present	Definite or high likelihood of viable tumor within the margins of Treated Lesion	Arterial phase hyperenhancement (with or without washout) OR Arterial phase isoenhancement (with or without washout)

Perilesional Tumor Viability

	Conceptual definition	CEUS Imaging Criteria
Absent	Low or negligible likelihood of viable tumor in close proximity to the outer margins of Treated Lesion	Enhancement identical to surrounding liver
Uncertain	The presence and the absence of viable tumor in close proximity to the outer margins of Treated Lesion each have similar probability	Arterial phase hyperenhancement without washout OR Arterial phase isoenhancement with washout OR Arterial phase hypoenhancement
Present	Definite or high likelihood of viable tumor in close proximity to the outer margins of Treated Lesion	Arterial phase hyperenhancement with washout



- New distinct nodule(s) separate from Treated Lesion should be categorized using CEUS Diagnostic Algorithm instead of CEUS TRA Algorithm.
- In patients after partial hepatectomy the entire resection margin should be evaluated using Perilesional Tumor Viability criteria. In patients without surgical cavity visible on B-mode ultrasound Intralesional Tumor Viability should be labeled as “Absent”.

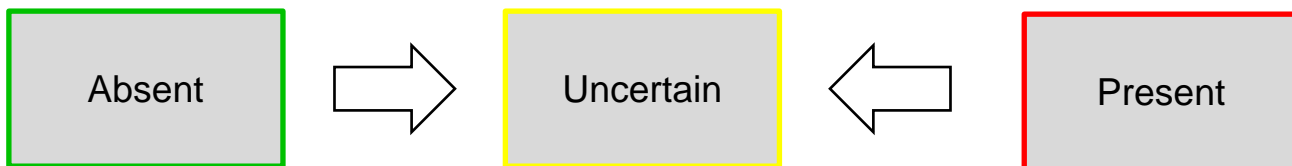


Step 2. Apply Tiebreaking Rule if Needed

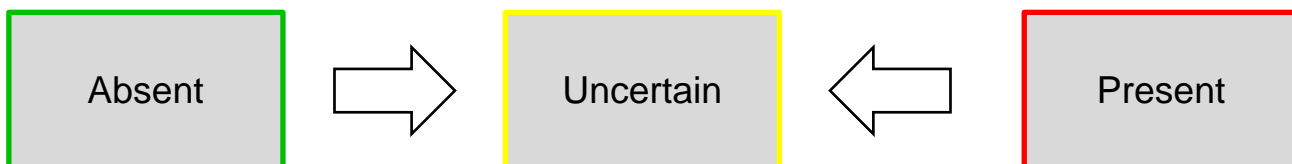
If unsure between two categories, choose the one reflecting lower certainty as illustrated below



Intralesional tumor viability



Perilesional tumor viability





Step 3. Reconcile Intralesional AND Perilesional Tumor Viability

To reconcile **perilesional** AND **intralesional** Tumor Viability, use the higher category of the two.

- If one or both are Present -> Final category **LR-TR Viable**
- If one is Uncertain and one is Absent -> Final category **LR-TR Equivocal**
- If both are Absent -> Final category **LR-TR Nonviable**

		<u>Intralesional</u> Tumor Viability		
		Absent	Uncertain	Present
Perilesional Tumor Viability	Absent	LR-TR Nonviable	LR-TR Equivocal	LR-TR Viable
	Uncertain	LR-TR Equivocal	LR-TR Equivocal	LR-TR Viable
	Present	LR-TR Viable	LR-TR Viable	LR-TR Viable

Step 4. Final check.

After steps 1, 2, 3 and 4 – Ask yourself if the assigned TRA category is reasonable and appropriate.

If YES: You are done, move on to the next treated lesion (if any)

If NO: Re-evaluate



LI-RADS® CEUS NONRADIATION TRA v2024

Technical Recommendations

Examiner Training

Appropriate ultrasound examiner and reader training is of paramount importance for successful CEUS LI-RADS TRA implementation. An appropriately trained CEUS examiner should be able to perform a thorough CEUS examination of the liver including documentation of all relevant contrast-enhancement phases. An examiner should also have sufficient knowledge of ultrasound contrast agent administration, image optimization and artifact reduction (1) and the appropriate skills to manage rare contrast reactions.

CEUS Imaging

CEUS should be performed in accordance with technical recommendations from the ACR CEUS LI-RADS working group (2) and ACR–AIUM–SRU practice parameter for the performance of CEUS (3).

Equipment

The US scanners must be equipped with appropriate software and hardware packages for CEUS. The transducer choice is typically based on the depth and size of the examined Treated Lesion. In the vast majority of cases, CEUS examinations of the liver will be performed using a lower-frequency curved array transducer, with higher frequency and linear array transducers reserved for select superficially located lesions when curved array transducers provide suboptimal visualization.

Contrast Agents

Currently, there are two purely intravascular US contrast agents widely used for liver imaging.

- Lumason (sulfur hexafluoride lipid-type A microspheres, Bracco Diagnostics Inc.), marketed as SonoVue outside of the United States.
- Definity (perflutren lipid microsphere, Lantheus Medical Imaging Inc.), marketed as Luminity outside of North America.

References:

1. [Fetzer DT et al, RadioGraphics 2023](#)
2. [Lyshchik A et al, Abdominal Radiology \(NY\) 2018](#)
3. [ACR–AIUM–SRU practice parameter for the performance of CEUS](#)



LI-RADS® CEUS NONRADIATION TRA v2024

Technical Recommendations

Patient positioning and pre-contrast examination

Most commonly, the patient is positioned supine with the right arm in abduction. After an optimal acoustic window is selected, B-mode images and measurements of a Treated Lesion are obtained.

Contrast agent administration

Contrast agent dose: The contrast dose can be adjusted based on the sensitivity of the equipment used for CEUS examination, patient size, and condition of the liver. Contemporary US devices and software allow for smaller doses than those listed on the package inserts. Typical dose of Lumason/SonoVue for liver imaging is 1.0-2.4ml. Typical dose of Definity/Luminity for liver imaging is 0.2-0.4ml.

Contrast agent injection: US contrast agent administration should be performed through an 18-22G peripheral intravenous line. If present, central venous lines and infusion ports can also be used following institutional protocols and aseptic techniques. The bolus of contrast should be immediately followed by a 5-10 mL normal saline flush.

Imaging protocol

To maximize benefits of real-time CEUS imaging and to preserve enough contrast agent to improve contrast washout detection, use the following recommended imaging protocol:

- Imaging should be performed continuously from contrast injection until peak arterial phase (AP) enhancement to capture peak AP enhancement and characterize the presence and pattern of AP enhancement while scanning through the entire Treated Lesion and its immediate surroundings. Alternatively, continuous imaging could be extended beyond peak AP enhancement until 60 sec. After 60 sec, imaging should be performed intermittently (5-10 sec every 30-60 sec) to detect and characterize washout.

Reference:

[Lyshchik A et al, *Abdominal Radiology \(NY\)* 2018](#)



LI-RADS® CEUS NONRADIATION TRA v2024 Lexicon

Lexicon	Definition
Viability	<p>Presence of live tumor cells within or along the margin of a Treated Lesion.</p>
Treated Lesion	<p>After <u>catheter-based treatments</u> (TAE, cTACE, DEB-TACE):</p> <ul style="list-style-type: none"> • Treated observation, visible on B-mode US <p>After <u>percutaneous treatments</u> (RFA, MWA, PEA):</p> <ul style="list-style-type: none"> • Combination of observation and parenchymal changes related to ablation procedure • Visible on B-mode US <p>After <u>surgical resection</u>:</p> <ul style="list-style-type: none"> • Surgical cavity after segmental or wedge resection visible on B-mode US
Intralesional Contrast Enhancement	<p>Contrast enhancement within the margins of Treated Lesion</p> <p><i>Note:</i></p> <ul style="list-style-type: none"> • Margins of Treated Lesion delineated on B-mode images • Contrast enhancement assessed on corresponding CEUS images
Perilesional Contrast Enhancement	<p>Contrast enhancement in close proximity to the outer margins of Treated Lesion</p> <p><i>Note:</i></p> <ul style="list-style-type: none"> • Margins of Treated Lesion delineated on B-mode images • Contrast enhancement assessed on corresponding CEUS images • Liver margin after surgical resection is considered perilesional tissue
Intralesional Tumor Viability	<p>Presence of live tumor cells within the margin of the treated lesion. Intralesional tumor viability predominantly assessed in the arterial phase, where presence of intralesional arterial phase hyperenhancement or isoenhancement indicates viable disease</p> <p><i>Note:</i></p> <ul style="list-style-type: none"> • Detection of washout is often not necessary for intralesional tumor viability assessment but could increase diagnostic confidence of intralesional tumor viability • In patients without surgical cavity visible on B-mode ultrasound Intralesional Tumor Viability should be labeled as “Absent”
Perilesional Tumor Viability	<p>Presence of live tumor cells along the margin of the treated lesion. Perilesional tumor viability must be assessed in the arterial, portal and late imaging phases.</p> <p><i>Note:</i></p> <ul style="list-style-type: none"> • Detection of washout is critical for accurate perilesional tumor viability characterization since perilesional arterial phase hyperenhancement + washout is consistent with perilesional tumor viability • In patients after partial hepatectomy the entire resection margin should be evaluated using Perilesional Tumor Viability criteria



LI-RADS® CEUS NONRADIATION TRA v2024

Limitations

Pathological correlation

LR-TR Nonviable does not imply complete pathologic response. Imaging in general is insensitive to microscopic or small foci of residual tumor that may be detectable only at histologic evaluation.

Biopsy proven HCC in LR-3 nodules

For biopsy proven HCC in LR-3 nodules with AP isoenhancement and no washout on pre-treatment CEUS, perilesional treatment response evaluation on CEUS could be challenging and alternative imaging modality, such as CT/MRI or interval imaging follow-up might be necessary for further characterization.

Biopsy proven HCC in nodules with AP hypoenhancement

For extremely rare cases of biopsy proven HCC in nodules with AP hypoenhancement pre-treatment CEUS, both intralesional and perilesional treatment response evaluation on CEUS could be challenging and alternative imaging modality, such as CT/MRI or interval imaging follow-up might be necessary for further characterization.

Treatment response assessment for radiation-based or systemic therapies

The current version of CEUS LI-RADS TRA does not include assessment of radiation-based or systemic therapies, since only limited data on the use of CEUS to monitor response to these treatments currently exist.

Ultrasound contrast agents

The current version of CEUS LI-RADS TRA does not include the use of purely intravascular ultrasound contrast agent Optison (perflutren protein-type A microspheres, GE Healthcare, Marlborough, MA USA) and contrast agent with a delayed Kupffer cell phase Sonazoid (perfluorobutane microspheres, GE Healthcare, Oslo, Norway), since only limited data on the use of these contrast agents to monitor HCC treatment response currently exist.



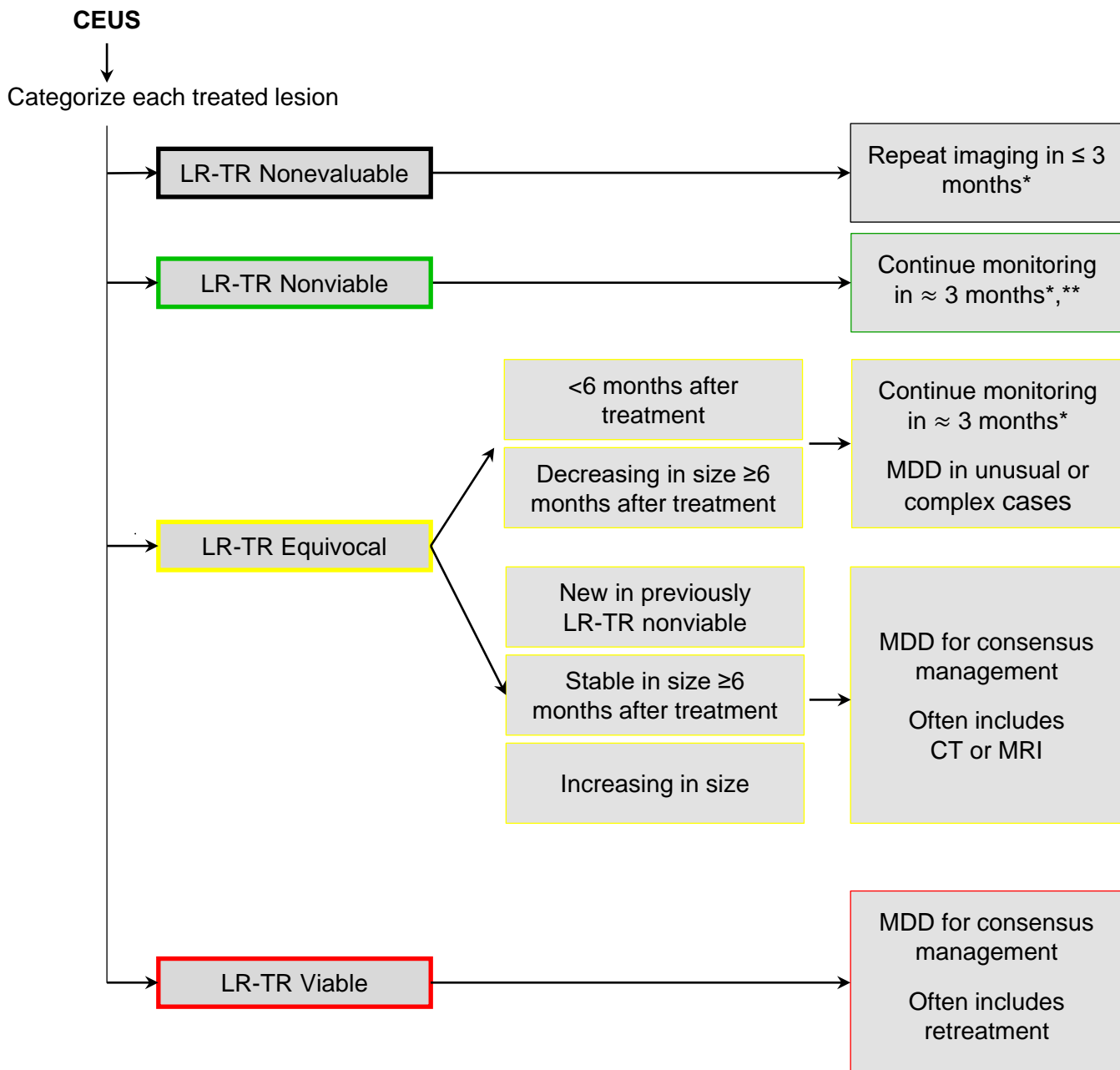
LI-RADS® CEUS NONRADIATION TRA v2024

Management

Suggested Imaging Workup Options & Time Intervals

Timing of CEUS imaging after LRT

- CEUS Nonradiation TRA LI-RADS does not include any specific guidelines on timing of CEUS imaging after LRT.
- The decisions on the most appropriate timing and imaging modality to evaluate HCC treatment response after LRT should be deferred to regional guidelines and MDD.



* Using same modality or different modality as appropriate

** If stable after 1-2 years, follow-up interval may be extended to 6 months



LI-RADS® CEUS NONRADIATION TRA v2024 Reporting

Use your judgment and common sense

If a patient has multiple treated lesions or has both treated lesions and untreated observations:

- Decide whether to report treated lesions and untreated observations individually, in aggregate, or as a combination of both, with the goal of communicating your findings and impression most clearly.

Tailor your recommendations to your patient

Avoid language that compels retreatment or change in treatment

If there are one or more treated lesions with viable tumor (i.e., LR-TR Viable) and consideration for retreatment or change in treatment is appropriate, the following phrases might be used:

- “Recommend MDD for consensus management”
 - “Consider MDD for consensus management”
-

Do NOT use CEUS Nonradiation TRA LI-RADS for patients after radiation-based or systemic therapy

Instead, use institutional or RECIST-type approach for interpretation and reporting in such patients. Often, aggregate reporting with more detailed description of select target lesions may be appropriate.



LI-RADS® CEUS NONRADIATION TRA v2024 Reporting

Treated lesion	Reporting requirement	Recommended report content
LR-TR Nonevaluable	<p>Must be reported in Findings and Impression</p> <p>May summarize in aggregate for clarity</p>	<p>Provide</p> <ul style="list-style-type: none"> • pretreatment category and size • current response category (Nonevaluable) • causative technical limitations or artifacts, and work-up suggestions
LR-TR Nonviable	<p>Must be reported in Findings and Impression</p> <p>May summarize in aggregate for clarity</p>	<p>Provide</p> <ul style="list-style-type: none"> • pretreatment category and size • current response category (Nonviable) • change since prior
LR-TR Equivocal	<p>Must be reported in Findings and Impression</p> <p>May summarize in aggregate for clarity</p>	<p>Provide</p> <ul style="list-style-type: none"> • pretreatment category and size • current response category (Equivocal or Nonprogressing) • change since prior
LR-TR Viable	<p>Must be reported in Findings and Impression</p> <p>May summarize in aggregate for clarity</p>	<p>Provide</p> <ul style="list-style-type: none"> • pretreatment category and size • current response category (Viable) • change since prior

All individually reported observations and treated lesions should include

- **Identifier:** sequential number or other unique identifier, kept fixed on all exams.
- **Image identifier (timing) where imaging features were assessed.** If possible, also save key images on PACS.



- New or untreated observations outside treatment zone: refer to **CEUS Diagnostic Core**
- After systemic therapy: report using **institutional or RECIST-type approach**.



LI-RADS® CEUS NONRADIATION TRA v2024 Reporting Template

Sample report: template A

Treated lesion [#] – A lesion in segment [Couinaud segment] (series [#], image [#]), pretreatment category LR [category from preprocedure diagnostic report] [dated], was treated with [treatment type: RFA/MWA/PEA/TAE/DEB-TACE/cTACE/focal resection/segmentectomy/partial hepatectomy]. The posttreatment follow-up shows a [size] [mm/cm] treated lesion [with/without/uncertain/ intralesional tumor viability]. Surrounding liver parenchyma enhancement consistent with [present/uncertain/absent tumor viability]. [Additional comments/descriptions]. After reconciling intralesional and perilesional tumor viability, LR-TR category (v2024) is established as: [Nonevaluable/Nonviable/Equivocal/Viable].

Sample report: template B

Treated lesion #:	1/2/3/4/5
Location:	Segment I/II/III/IVa/IVb/V/VI/VII/VIII
Pretreatment category	[Uncertain/Not seen/Remote treatment/LR-5/LR-4/LR-3/TIV/LR-M/Biopsy HCC]
Type of most recent treatment:	[RFA/MWA/PEA/TAE/DEB-TACE/cTACE/Unknown]
Date of most recent treatment:	[MM-DD-YYYY/Unknown]
Intralesional tumor viability:	[Present/Absent/Uncertain/Nonevaluable]
Perilesional tumor viability:	[Present/Absent/Uncertain/Nonevaluable]
LR-TR category:	[Nonevaluable/Nonviable/Equivocal/Viable]

Notes:

- The above sample reports are meant as guidance. The report elements, order of report elements, terminology, and other details should be customized to match institutional preference.
- LI-RADS measurements are given in mm, but each institution should utilize units according to local standards and use them consistently.
- Observations may be treated sequentially by different types of therapies. Use your judgment to select the appropriate TRA algorithm in such cases. You may not know which therapy was used. If the type of therapy can be inferred from imaging features, apply the appropriate TRA algorithm.

Reference: [Roudenko A et al, J Vasc Interv Radiol 2023](#)



Intralesional Tumor Viability Absent

Conceptual definition:

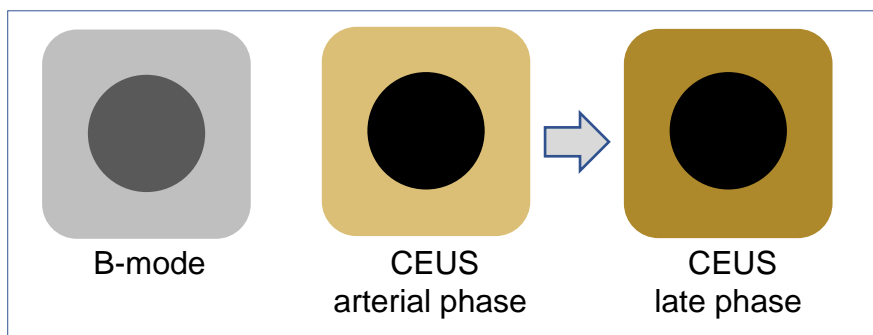
Low or negligible likelihood of viable tumor after treatment within the margins of the Treated Lesion

Criterion:

No enhancement within the margins of the Treated Lesion.

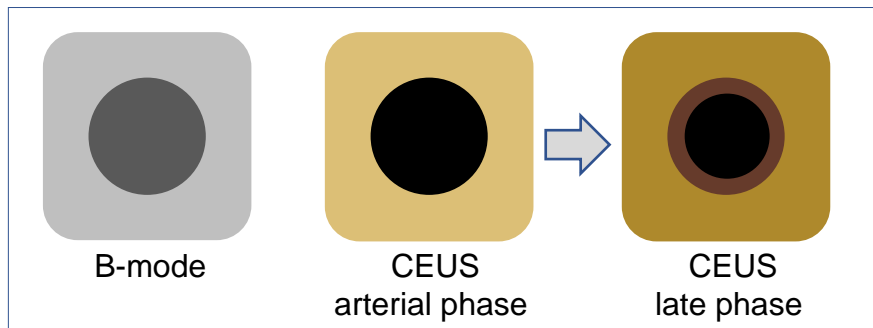
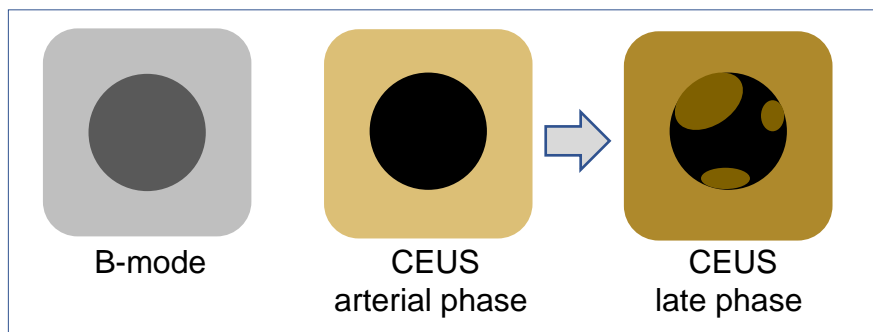
If unsure

Absent vs. Uncertain -> Uncertain



Granulation tissue enhancement

In rare cases, granulation tissue within the Treated Lesion could demonstrate mild hypoenhancement. This uncommon appearance should not be confused with Intralesional Tumor Viability.

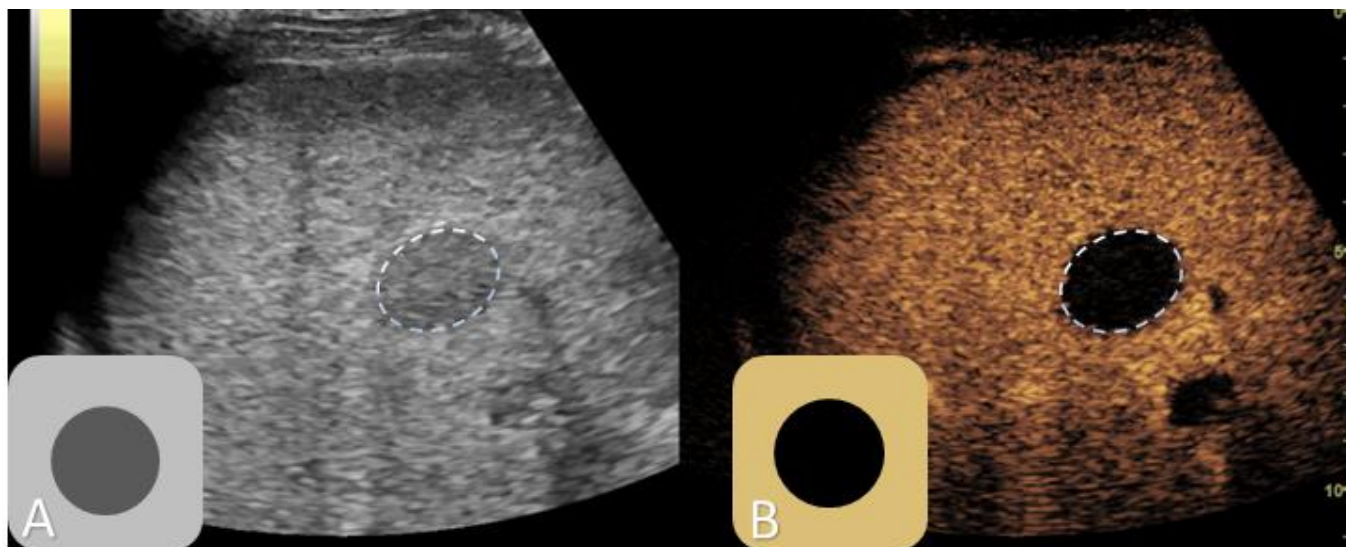




Intralesional Tumor Viability Absent

Criterion:

No enhancement within the margins of the Treated Lesion.



Intralesional Tumor Viability **Absent**. 1-month post TACE.

(A) B-mode images used as an anatomical reference to define Treated Lesion margins (dotted line).

(B) Arterial phase CEUS image demonstrates No enhancement within the margins of the Treated Lesion (dotted line).



Intralesional Tumor Viability Uncertain

Conceptual definition:

The presence and the absence of viable tumor within the margins of Treated Lesion each have similar probability.



Criterion:

Arterial phase hypoenhancement within the margins of Treated Lesion (with or without washout).

If unsure

Uncertain vs. Absent -> Uncertain

Uncertain vs. Present -> Uncertain

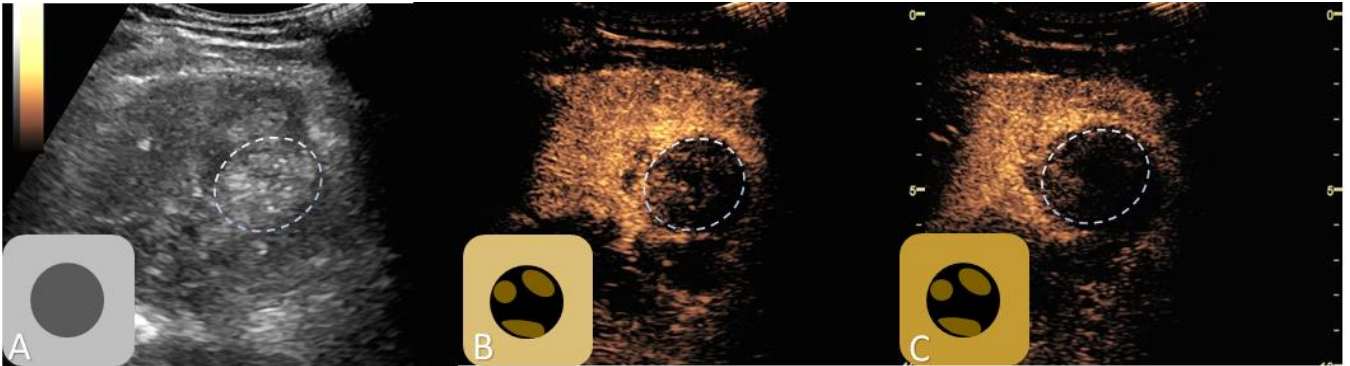




Intralesional Tumor Viability Uncertain

Criterion:

Arterial phase hypoenhancement within the margins of Treated Lesion (with or without washout).



Intralesional Tumor Viability **Uncertain**. 1-month after microwave ablation.

(A) B-mode images used as an anatomical reference to define Treated Lesion margins (dotted line).

(B) Arterial phase CEUS image demonstrates irregular, peripheral intralesional hypoenhancement within the margins of the Treated Lesion (dotted line).

(C) Late phase CEUS image demonstrated some degree of contrast washout within the margins of the Treated Lesion (dotted line).



Intralesional Tumor Viability Present

Conceptual definition:

Definite or high likelihood of viable tumor within the margins of Treated Lesion

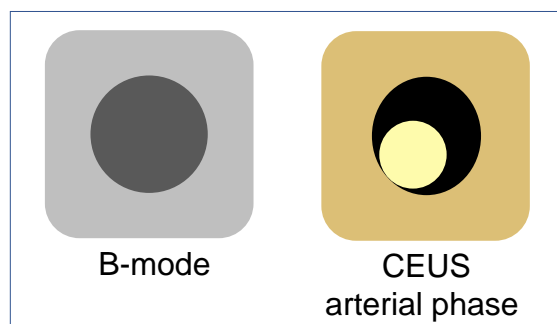
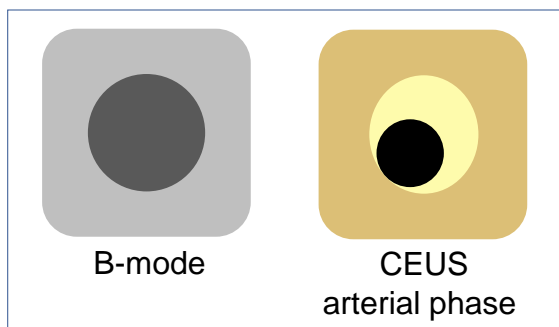
Criteria:

One of the following:


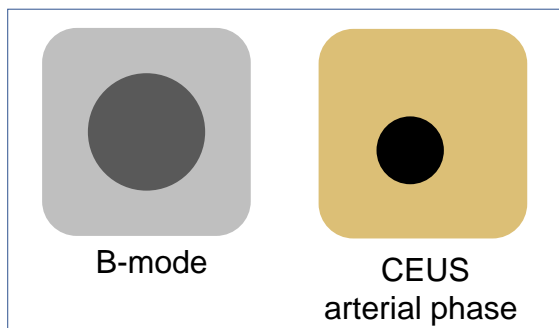
- Arterial phase hyperenhancement (with or without washout) OR
- Arterial phase isoenhancement (with or without washout)

If unsure

Present vs. Uncertain -> Uncertain



Arterial phase hyperenhancement within the margins of Treated Lesion (with or without washout).



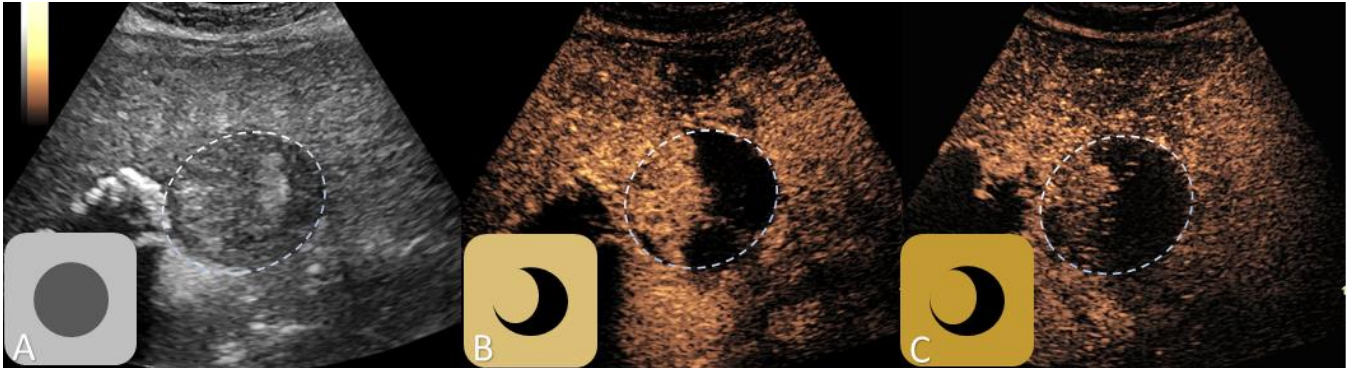Arterial phase isoenhancement within the margins of Treated Lesion (with or without washout).



Intralesional Tumor Viability Present

Criterion:

Arterial phase hyperenhancement or isoenhancement within the margins of the Treated Lesion (with or without washout).



Intralesional Tumor Viability **Present**. 1-week post transarterial chemoembolization.

(A) B-mode images used as an anatomical reference to define Treated Lesion margins (dotted line).
(B) Arterial phase CEUS image demonstrates nodular intralesional area of contrast iso-enhancement within the margins of the Treated Lesion (dotted line).

(C) Late phase CEUS image demonstrated some degree of contrast washout within the margins of the Treated Lesion (dotted line).



Perilesional Tumor Viability Absent

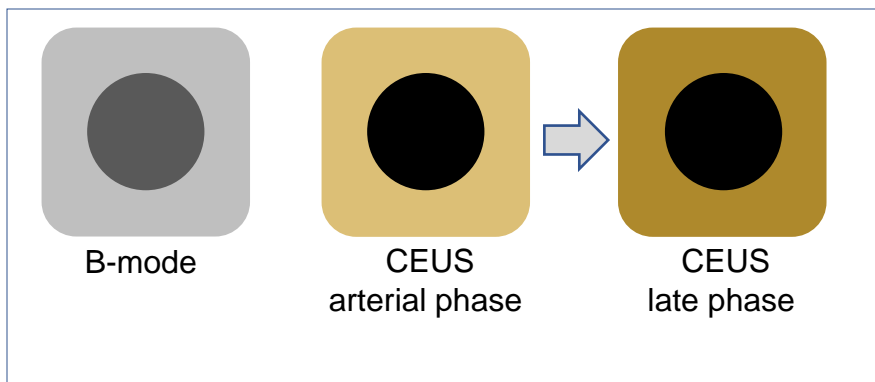
Conceptual definition:

Low or negligible likelihood of viable tumor in close proximity to the outer margins of Treated Lesion.

Criterion:

Parenchymal enhancement in close proximity to the outer margins of Treated Lesion identical to surrounding liver.

If unsure Absent vs. Uncertain -> Uncertain

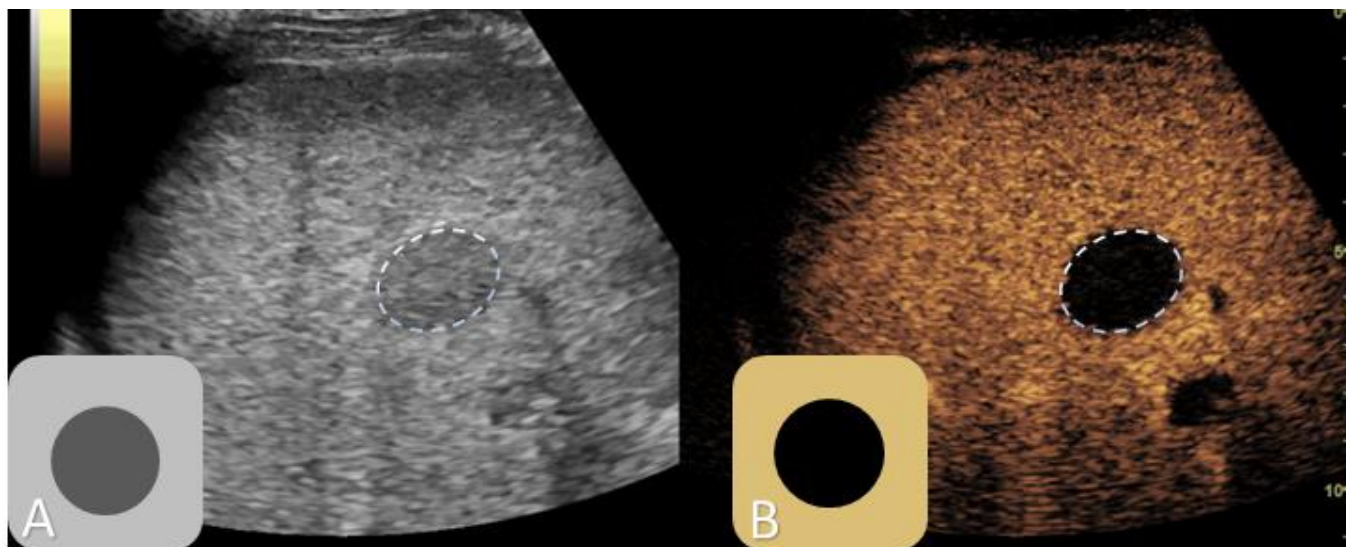
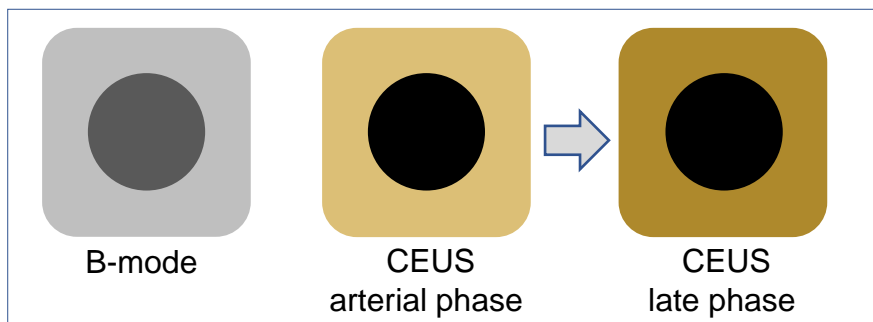




Perilesional Tumor Viability Absent

Criterion:

Enhancement identical to surrounding liver.



Perilesional Tumor Viability **Absent**. 1-month post TACE.

(A) B-mode images used as an anatomical reference to define Treated Lesion margins (dotted line).
(B) Arterial phase CEUS image demonstrates normal enhancement in close proximity to margins of Treated Lesion (dotted line).



Perilesional Tumor Viability Uncertain

Conceptual definition:

The presence and the absence of viable tumor in close proximity to the outer margins of Treated Lesion each have moderate probability

Criteria:

One of the following:

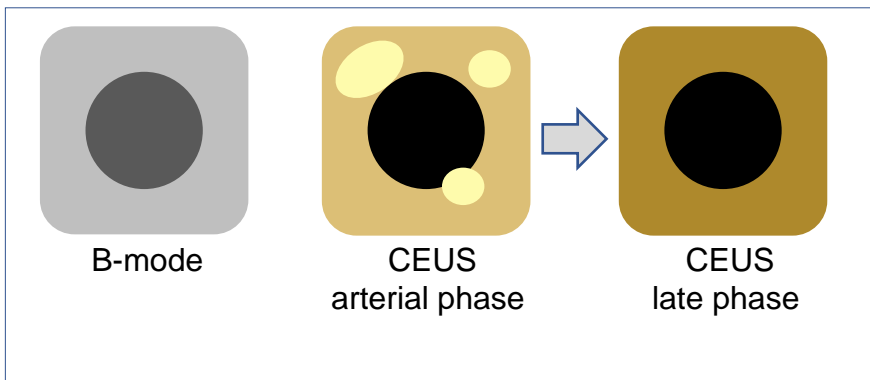
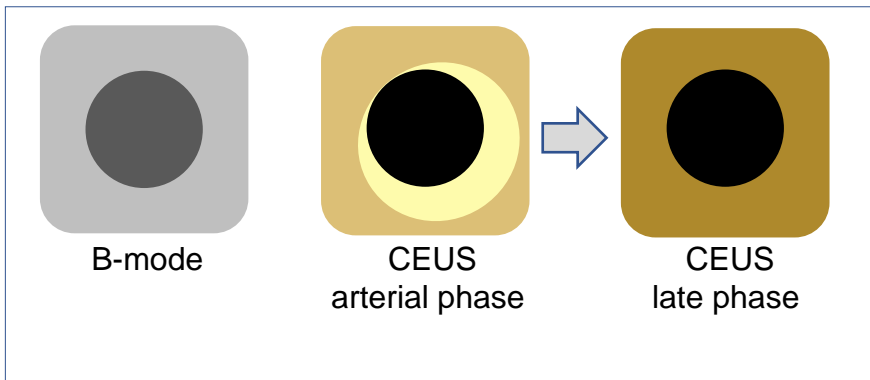
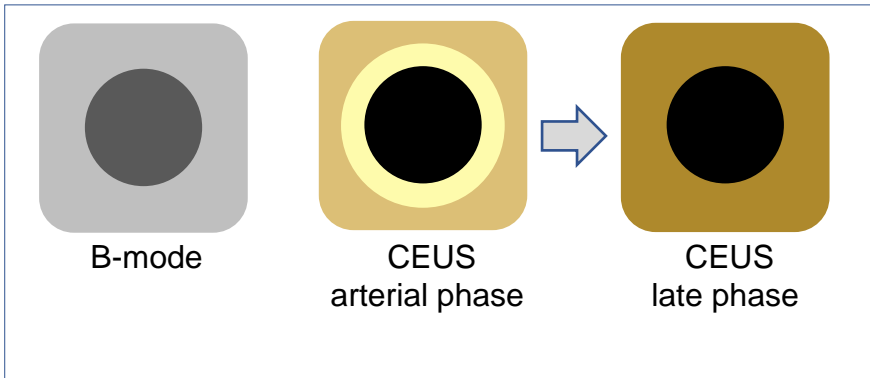
- Arterial phase hyperenhancement without washout OR
- Arterial phase isoenhancement with washout OR
- Arterial phase hypoenhancement

If unsure

Uncertain vs. Absent -> Uncertain
Uncertain vs. Present -> Uncertain



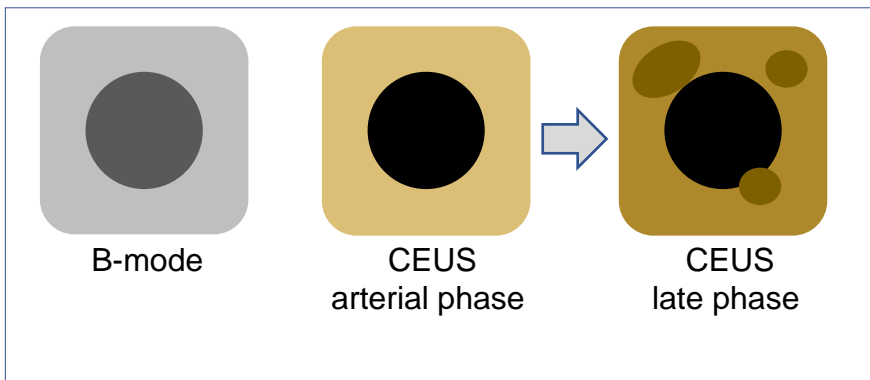
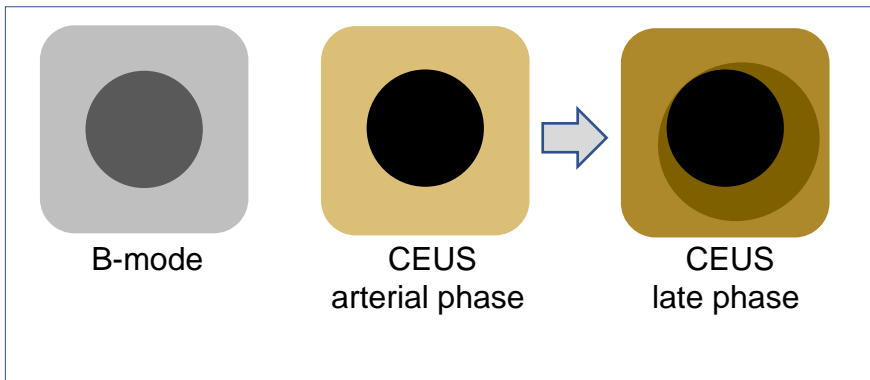
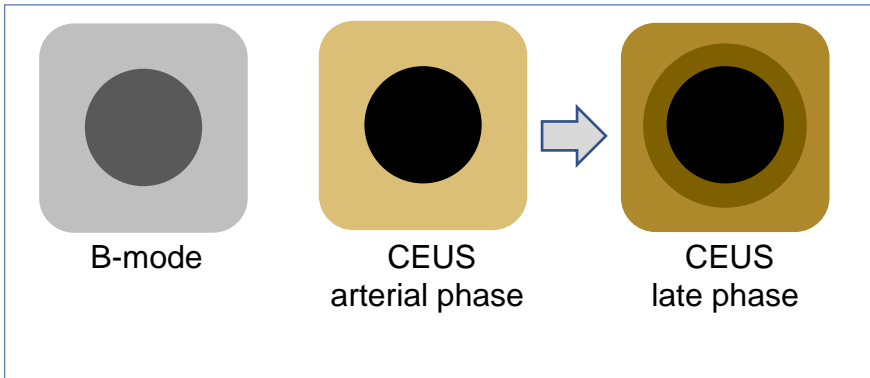
Perilesional Tumor Viability Uncertain



Arterial phase hyperenhancement without washout
 OR
Arterial phase isoenhancement with washout
 OR
Arterial phase hypoenhancement



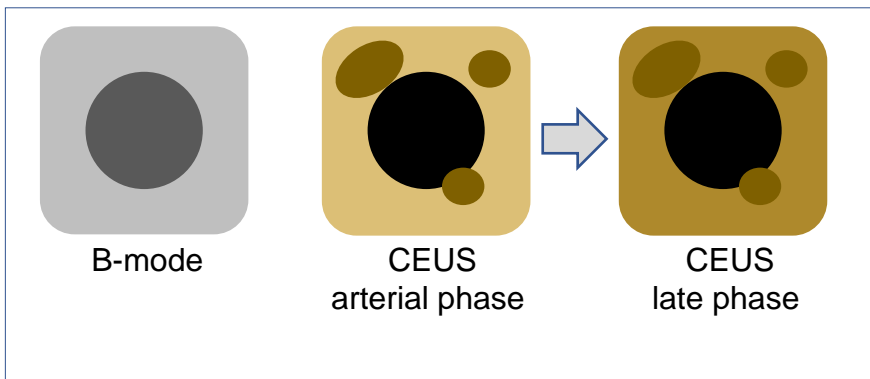
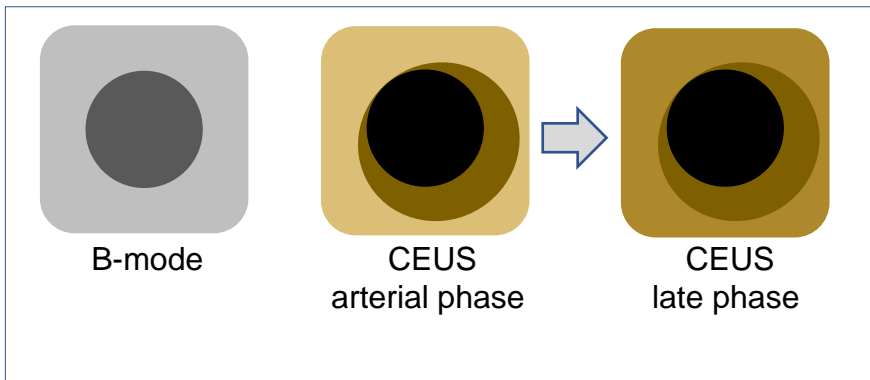
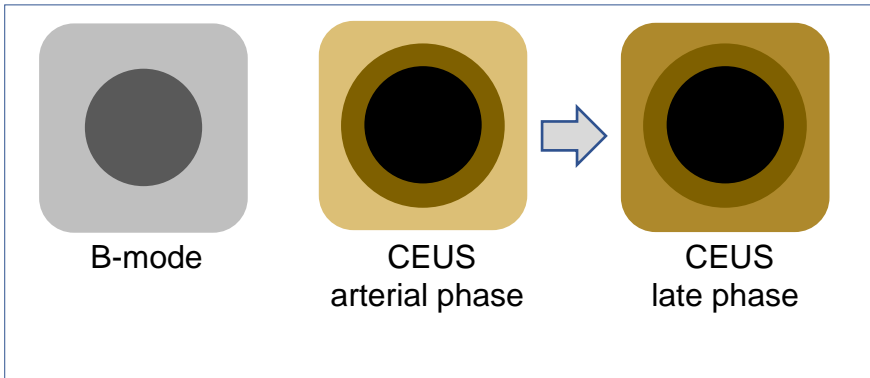
Perilesional Tumor Viability Uncertain



Arterial phase hyperenhancement without washout
OR
Arterial phase isoenhancement with washout
OR
Arterial phase hypoenhancement



Perilesional Tumor Viability Uncertain



Arterial phase hyperenhancement without washout
OR
Arterial phase iso-enhancement with washout
OR
Arterial phase hypo-enhancement

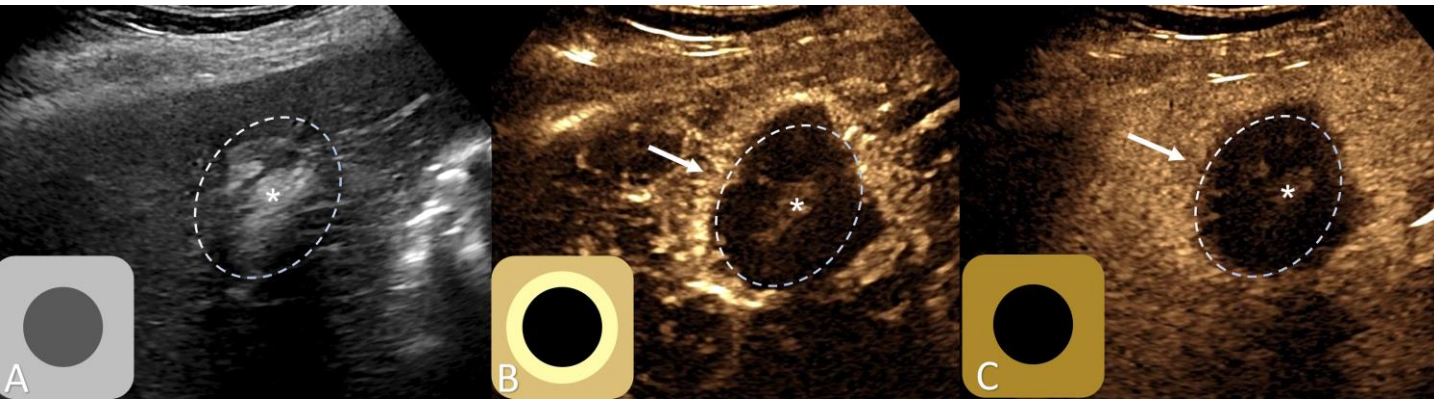


Perilesional Tumor Viability Uncertain

Criteria:

One of the following:

- Arterial phase hyperenhancement without washout OR
- Arterial phase isoenhancement with washout OR
- Arterial phase hypoenhancement



Perilesional Tumor Viability **Uncertain**. Immediately after radiofrequency ablation.

(A) B-mode images used as an anatomical reference to define Treated Lesion margins (dotted line).

(B) Arterial phase CEUS image demonstrates nodular perilesional rim of hyperenhancement (arrow) adjacent to the margins of the Treated Lesion (dotted line).

(C) Late phase CEUS image demonstrated no detectable contrast washout in previously hyperenhanced area (arrow) along the margins of the Treated Lesion (dotted line). (*) pseudoenhancement artifact from hyperechoic post-ablation changes in the center of treated lesion.



Perilesional Tumor Viability Present

Conceptual definition:

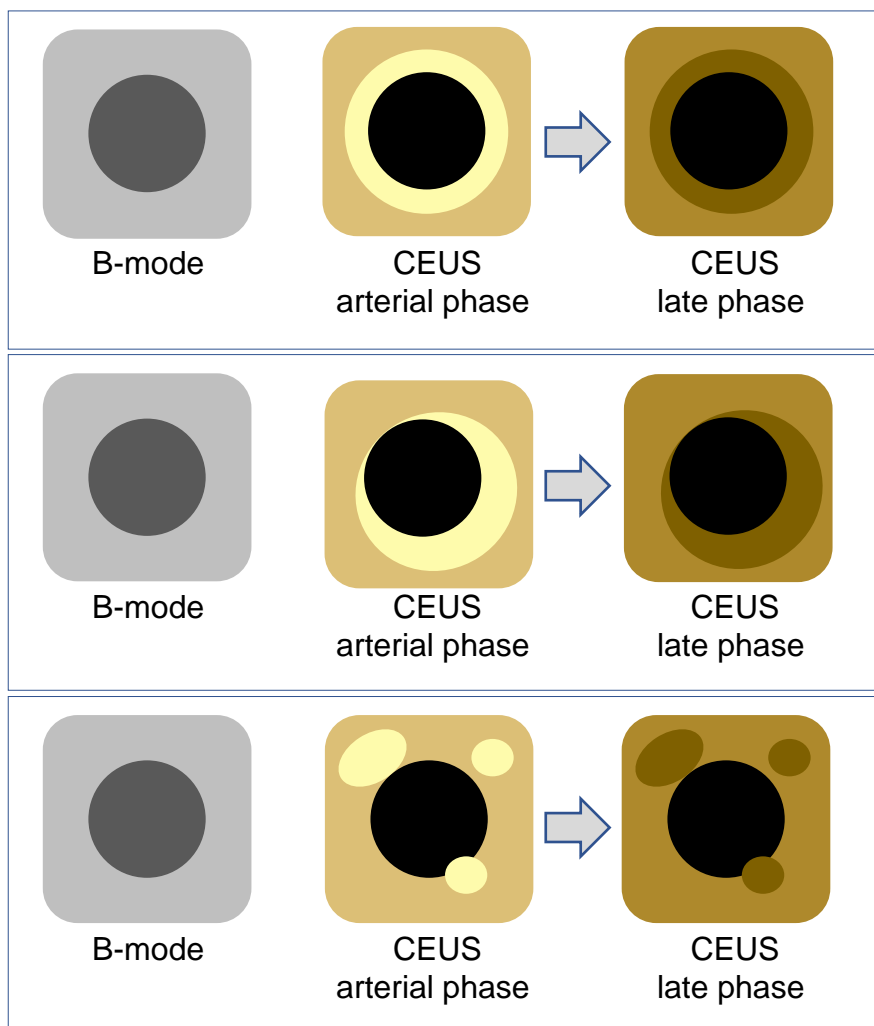
Definite or high likelihood of viable tumor in close proximity to the outer margins of Treated Lesion

Criterion:

Arterial phase hyper-enhancement with washout in close proximity to the outer margins of Treated Lesion.

If unsure

Present vs. Uncertain -> Uncertain

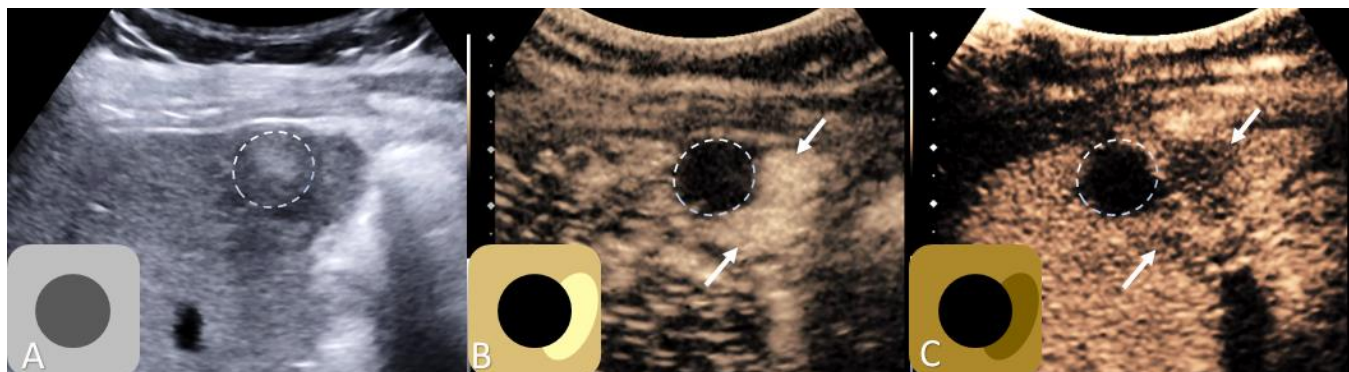




Perilesional Tumor Viability Present

Criterion:

Arterial phase hyper-enhancement with washout in close proximity to the outer margins of Treated Lesion.



Perilesional Tumor Viability **Present**. 1-month post- microwave ablation.

(A) B-mode images used as an anatomical reference to define Treated Lesion margins (dotted line).

(B) Arterial phase CEUS image demonstrates nodular perilesional area of hyperenhancement (arrows) adjacent to the margins of the Treated Lesion (dotted line).

(C) Late phase CEUS image demonstrated mild washout in previously hyperenhanced area (arrows) along the margins of the Treated Lesion (dotted line).



Posttreatment Imaging after Nonradiation-Based LRT: What should the radiologist know?

What should the radiologist know about the treated lesion or the treated lesion margin after nonradiation-based thermal (RFA, MWA) or chemical (PEA) ablation?

Tumor response after ablation (RFA, MWA, PEA) occurs immediately and is attributable to heat-induced (RFA, MWA), or chemical-induced (PEA) cell death via denaturation and coagulation necrosis of targeted tissue.

- For thermal ablation: treatment zone should be larger (~ 10 mm) initially. (The goal is to ablate not only the lesion but also some parenchyma to kill any microscopic disease around the tumor).
- For chemical ablation: the treatment zone is usually the same size as the pretreatment lesion.
- For all types of ablation: gradual decrease in size of the Treated Lesion over time.
- Foci of gas can be seen early post-ablation but should disappear by 7-10 days post-ablation. Persistent gas bubbles or new bubbles suggest developing abscess.

What should the radiologist know about the treated lesion or the treated lesion margin after nonradiation-based intra-arterial embolization?

Tumor response after nonradiation-based intra-arterial embolic therapies (TAE, cTACE, DEB-TACE) occurs immediately and is due to chemotoxic injury from the administered chemotherapeutic agent (cTACE, DEB-TACE) or ischemic injury from arterial embolization (TAE, cTACE, DEB-TACE).

- TAE, also known as ‘bland’ hepatic artery embolization, is performed with a mixture of contrast and small particles (ie. Polyvinyl alcohol, gelfoam, embospheres) which occludes the tumor’s blood supply. Anti-tumor effects are via ischemia and infarction of tumor.
- cTACE (conventional TACE) is performed by emulsifying aqueous chemotherapeutic agents into iodized oil, which acts as the drug-transport agent. Anti-tumor effects are via ischemia and infarction, as well as chemotoxic injury.
- DEB-TACE (drug eluting bead-TACE) is performed with drug-loaded microspheres that release chemotherapeutic agents in a controlled manner after embolization. Anti-tumor effects are via ischemia and infarction, as well as chemotoxic injury.
- Intralesional echogenic material can be seen for several days-weeks after TACE (intraprocedural air, or embolic agents). Persistent or new intralesional gas may suggest developing abscess.



Posttreatment Imaging after Nonradiation-Based LRT: What should the radiologist know?

Expected imaging appearance of intralesional nonviable tumor after Nonradiation LRT

- No residual enhancement of the targeted lesion.

Expected imaging appearance of intralesional viable tumor after Nonradiation LRT

- Hyperenhancement or isoenhancement (compared to the surrounding liver).
 - Intralesional tumor viability is predominantly assessed in the AP, where presence of intralesional APHE or isoenhancement indicates viable disease. Documentation of washout is often not necessary for intralesional tumor viability assessment, though can increase diagnostic confidence of intralesional tumor viability detection.

Expected imaging appearance of liver parenchyma surrounding Treated Lesion after Nonradiation LRT

- Parenchymal perfusional and inflammatory changes, which may vary in size and intensity.
 - Typically: Rim of hyperenhancement surrounding treated lesion *without* washout.
 - Occasional: wedge-shaped or geographic areas of decreased enhancement as a result of injury to normal liver parenchyma.
- Enhancement surrounding a linear hypoenhancing track extending from the treatment zone toward the liver capsule may be seen after percutaneous ablation. This is attributable to the needle track itself or to track ablation (frequently performed as part of RFA or MWA).
- Above changes are usually temporary and resolve within 3-6 months after treatment.

Expected imaging appearance of perilesional viable tumor after Nonradiation LRT

- **Perilesional:** APHE with washout in close proximity to margins of Treated Lesion.
 - Perilesional tumor viability must be assessed in the arterial, portal, and late imaging phases. Detection of washout is critical for accurate perilesional tumor viability characterization.
 - Perilesional APHE *without* washout is typical for post-procedure inflammatory changes.
 - Perilesional APHE *with* washout is consistent with perilesional tumor viability.



Frequently Asked Questions

Getting Started

The LI-RADS TRA Cores are long. Do I need to know everything in the Cores?

The essential component of each TRA Core is the **streamlined 1-page layout**, which contains all four steps in each TRA algorithm. All other material is supplementary.

What is a Treated Lesion?

Path-proven or presumed (LR-3, LR-4, LR-5, LR-M) HCC or select cases of iCCA and cHCC-CCA that has been treated by locoregional therapies or surgical resection in patient at risk for HCC.

Definition of Treated Lesion depends on the LRT method as follows:

- Catheter-based treatments (TAE, cTACE, DEB-TACE): treated observation visible on B-mode US.
 - Percutaneous treatments (RFA, MWA, PEA): Combination of treated observation and parenchymal changes related to ablation procedure visible on B-mode US.
 - Surgical resection: Surgical cavity after segmental or wedge resection visible on B-mode US. In patients after partial hepatectomy, surgical margin visible on B-mode US is considered perilesional tissue.
-

Why “Treated Lesion” instead of “Treated Observation”?

“Treated Lesion” and “Treated Observation” are both acceptable. LI-RADS uses “Treated Lesion” in the TRA Cores, assuming that the targeted observation is a true lesion, rather than a pseudolesion.

What about lesions treated by radiation-based therapy?

LI-RADS CEUS Nonradiation TRA v2024 does not address response to radiation-based therapy at this time. As evidence accrues, future versions may include assessment of radiation-based LRTs.

What about lesions treated by systemic therapy?

LI-RADS CEUS Nonradiation TRA v2024 does not address response to systemic therapy.

A lesion targeted by ablation or embolic procedure is outside the treatment zone. How do I categorize the lesion?

If a targeted lesion is outside the treatment zone, it should be considered untreated. Apply the Diagnostic CEUS LI-RADS algorithm and categorize the targeted lesion is untreated.



Frequently Asked Questions Getting Started

Is there a time limit after which LI-RADS TRA no longer applies?

No. LI-RADS TRA can be applied indefinitely after LRT, even years after treatment.

How do I distinguish residual/recurrent tumor from new tumor adjacent to a treated observation?

Residual or recurrent tumor occurs in the lesion, or at the lesion margin, while new tumor occurs outside the margin. If in doubt about whether the area of concern is along the margin or outside the margin, assume it is at the margin and apply the TRA algorithm rather than the diagnostic algorithm.

Does LR-TR Nonviable exclude microscopic viability?

No. LR-TR Nonviable means there is no imaging evidence of gross viable tumor, but small foci of live tumor cells cannot be excluded by noninvasive imaging.

Do I need to assess response of each treated lesion if the number of such lesions is large?

While you need to assess the treatment response of each individual lesion, you may report treated lesions individually, in aggregate, or as a combination of both, in the manner that communicates your findings and impression most clearly.

For example:

“There are six treated lesions.

- Four are nonviable (treated lesions 2, 4, 5, 6).
 - Two are viable:
 - Treated lesion 1, segment III – LR-TR Viable 25 mm (pre-treatment LR-5, 35 mm).
 - Treated lesion 3, segment V – LR-TR Viable 12 mm (pre-treatment LR-5, 40 mm).”
-

What are parenchymal perfusional changes?

Treatment-related APHE or hypoenhancement of hepatic parenchyma.

Examples:

- Linear enhancement around hypoenhancing needle track after thermal ablation.
- Rim APHE without washout or geographic hypoenhancement peripheral to treated lesion or surgical margin.



Frequently Asked Questions Getting Started

Can the TRA algorithms be used in patients who are not at-risk for HCCs? For example, can they be used to assess response of colorectal cancer metastases to the liver in a patient without cirrhosis or chronic HBV infection.

Current LI-RADS algorithms apply ONLY to patients at risk for HCC. Thus, LI-RADS TRA algorithms do NOT apply to patients after locoregional therapy for primary liver cancers or metastases to the liver from extrahepatic origin, unless the primary liver cancer is HCC or the patient has cirrhosis or chronic HBV.

However, with caution, LI-RADS TRA concepts, imaging features, and criteria can be applied to assist in treatment response assessment in non-high-risk patients. For example:

- A colorectal cancer metastasis to the liver in a patient without cirrhosis or chronic HBV was treated by TACE. Pre-procedure imaging demonstrated rim enhancement followed by rapid washout. On post-TACE imaging, there is no intralesional enhancement with normally enhancing surrounding liver parenchyma. This could be interpreted and reported as “No viable disease”, but it should not be formally categorized and reported as “LR-TR Nonviable”.
- A neuroendocrine metastasis to the liver in a patient without cirrhosis or chronic HBV was treated by ablation. Pre-procedure imaging demonstrated APHE with rapid with marked washout. On post-ablation imaging, there is APHE within the margins of treated lesion. This could be interpreted and reported as “Viable”, but it should not be formally categorized and reported as “LR-TR Viable”.

Why Nonradiation TRA is separated from Radiation TRA assessment?

Emerging evidence indicates that nonradiation-based (RFA, MWA, cryoablation, PEA, TAE, cTACE, DEB-TACE) and radiation-based LRTs (TARE and SBRT), have different effects on the targeted tumor and surrounding liver. The current CEUS Nonradiation TRA LI-RADS provide algorithms for TRA only applicable to nonradiation- LRT.

In patients with multiple treated lesions, how many lesions could be reliably evaluated with single CEUS examination?

- CEUS is a lesion-based evaluation. The number of lesions that could be evaluated with a single CEUS examination depends on multiple patient-specific factors (acoustic window, lesion size and depth) as well as the examiner’s experience and level of confidence. As a general rule, up to 2 lesions could be reliably evaluated with single CEUS examination.

Can CEUS be used to evaluate extrahepatic disease?

- CEUS is generally a lesion-specific evaluation and cannot be used for disease staging.



Frequently Asked Questions Management

What is the optimal follow-up interval to assess treatment response?

Optimal follow-up interval depends on the applied treatment, individual patient's clinical conditions and risks, institutional guidelines, and reimbursement constraints (if applicable).

In general, follow-up imaging is recommended every 3 months, although earlier initial imaging may be helpful after certain locoregional therapies.

Also, immediate CEUS often performed after thermal ablation or embolization procedures to assess immediate tumor treatment response or occlusion of tumor arterial supply.

In patients with LR-TR Nonviable stable for 1-2 years, follow-up interval may be extended to 6 months.

Are there any pitfalls in assessing response too soon after treatment?

Treatment-related parenchymal perfusional changes may resemble or obscure tumor enhancement, potentially reducing diagnostic confidence or causing causing interpretation errors.

How do I determine if a treated lesion is nonevaluable?

LR-TR Nonevaluable should be assigned ONLY if treatment response cannot be meaningfully evaluated due to omission of required images (e.g., absence of one or more phases, failure of contrast injection, gross mistiming of the arterial phase, treated lesion not included in the field of view) or image degradation due to motion or other artifacts.

LR-TR Nonevaluable should NOT be assigned if image quality is adequate, even if imaging features are difficult to characterize or interpret. If imaging features are difficult to characterize or interpret, categorize as LR-TR Equivocal.

I recommended repeat imaging in ≤ 3 months, but the imaging was performed 4 months later. Is this a problem?

The timeframes are just suggestions. Actual scheduling may deviate for many reasons.



Frequently Asked Questions Management

A treated lesion is categorized as LR-TR Nonevaluable. The management page recommends repeat imaging in ≤ 3 months. What imaging modality should I recommend?

The choice of imaging modality for evaluating a treated lesion categorized as LR-TR Nonevaluable depends on several factors such as ability to correct the root cause, insurance authorization, patient preference, and scheduling issues. Guidelines for specific scenarios are listed below:

- Cause of image omission or degradation is correctable (e.g., translation services for language barriers, native-language breath-holding instructions, surmountable claustrophobia): recommend same modality.
- Cause of image omission or degradation is not correctable (e.g., prior anaphylactic reaction to a class of contrast agent, limited breath-holding capacity, unsurmountable claustrophobia): recommend different modality.
- Insurance will not authorize repeat imaging with same modality: recommend different imaging modality.
- Patient prefers a different modality: recommend patient's preferred modality unless an alternative modality would provide substantially better diagnostic performance.
- There is an unacceptably long scheduling delay for a particular alternative imaging modality (e.g., MRI): recommend a modality with shorter scheduling delay (e.g., CT).

What is the difference between residual and recurrent tumor and does the distinction matter?

- Residual disease refers to a lesion that was never completely treated and therefore categorized as viable immediately after treatment.
- Recurrent disease refers to a lesion that was completely treated and therefore categorized as nonviable initially after treatment, however, subsequently develops masslike enhancement.

Is the distinction between residual and recurrent tumor important?

Sometimes. Depending on the situation, this information can help guide the decision of whether to retreat with the same therapy or to switch to a different therapy.

Does LI-RADS provide formal guidance on the interpretation and reporting of residual versus recurrent disease?

- Not yet. Integration of the distinction between residual and recurrent disease into LI-RADS TRA reporting is a future direction.



Frequently Asked Questions

Treated biopsy proven HCC in LR-3 and LR-4

Can I apply the LI-RADS CEUS Nonradiation TRA to treated, path-proven HCC categorized as LR-3 and LR-4 on pretreatment CEUS?

- CEUS Nonradiation LI-RADS TRA can be used for treatment response assessment of HCC categorized as LR-3 or LR-4 on pretreatment CEUS.
- In these cases, review of pretreatment imaging is very important to increase accuracy of TRA.
- **Lesions with APHE without washout on pretreatment CEUS**
 - Intralesional tumor viability: Apply standard Intralesional tumor viability imaging criteria.
 - Perilesional tumor viability: Appearance similar to pre-treatment (APHE without washout), especially progressing or persisting ≥ 6 months is concerning for perilesional tumor viability and should be referred to MDD for further evaluation.
- **Lesions with AP isoenhancement and late/mild washout on pretreatment CEUS**
 - Intralesional tumor viability: Apply standard Intralesional tumor viability imaging criteria.
 - Perilesional tumor viability: Appearance similar to pre-treatment (isoenhancement with washout), especially progressing or persisting ≥ 6 months is concerning for perilesional tumor viability and should be referred to MDD for further evaluation.
- **Lesions with AP isoenhancement without washout on pretreatment CEUS**
 - Intralesional tumor viability: Apply standard Intralesional tumor viability imaging criteria.
 - Perilesional tumor viability: TRA will be very challenging in these cases, since the contrast enhancement could be indistinguishable from normal liver parenchyma. Therefore, most cases will likely benefit from surveillance with an alternative imaging modality.
- **Lesions with AP hypoenhancement with or without late and mild washout on pretreatment CEUS**
 - Intralesional tumor viability: TRA will be very challenging in these cases, since this appearance could be indistinguishable from post-treatment granulation tissue. Therefore, most cases will likely benefit from close follow-up or in some cases from alternative imaging modality.
 - Perilesional tumor viability: TRA will be very challenging in these cases, since the contrast enhancement could be indistinguishable post-treatment perfusion alterations. Therefore, most cases will likely benefit from close follow-up or in some cases from alternative imaging modality.



Frequently Asked Questions

Treated LR-M, Cholangiocarcinoma, Combined Tumor

Can I apply the treatment response algorithm to LR-M, path-proven cholangiocarcinoma, or path-proven combined HCC-cholangiocarcinoma?

LI-RADS CEUS Nonradiation TRA can be used in select cases for treatment response assessment of non-HCC malignancies, such as iCCA and cHCC-CCA as follows:

- **Lesions with APHE and early or marked washout on pretreatment CEUS**
 - Intralesional tumor viability: Apply standard Intralesional tumor viability imaging criteria.
 - Perilesional tumor viability: Apply standard Perilesional tumor viability imaging criteria.
- **Lesions with rim-enhancement on pretreatment CEUS**
 - Intralesional tumor viability: Apply standard Intralesional tumor viability imaging criteria.
 - Perilesional tumor viability: Apply standard Perilesional tumor viability imaging criteria, since in virtually all LR-M lesions rim-enhancement is followed by rapid and marked washout.
- **Lesions with AP isoenhancement and early or marked washout on pretreatment CEUS**
 - Intralesional tumor viability: Apply standard Intralesional tumor viability imaging criteria.
 - Perilesional tumor viability: Appearance similar to pre-treatment (isoenhancement with washout), especially progressing or persisting ≥ 6 months is concerning for perilesional tumor viability and should be referred to MDD for further evaluation.
- **Lesions with AP hypoenhancement and early or marked washout on pretreatment CEUS**
 - Intralesional tumor viability: TRA will be very challenging in these cases, since this appearance could be indistinguishable from post-treatment granulation tissue. Therefore, most cases will likely benefit from surveillance with an alternative imaging modality.
 - Perilesional tumor viability: TRA will be very challenging in these cases, since the contrast enhancement could be indistinguishable post-treatment perfusion alterations. Therefore, most cases will likely benefit from close surveillance or in select cases from an alternative imaging modality.

Are there any pitfalls in assessing treatment response of LR-M, path-proven cholangiocarcinoma, or path-proven combined HCC-cholangiocarcinoma after LRT?

Yes. There is limited literature on CEUS treatment response assessment of LR-M, iCCA and cHCC-CCA after LRT.



Frequently Asked Questions

Surgical Resection

What algorithm should I use for patients after surgical resection?

Use the LI-RADS CEUS Nonradiation TRA Algorithm to assess observations at the surgical margin after segmental or wedge resection, or partial hepatectomy.

The appearance of Treated Lesion depends on the amount of surgically removed liver.

- The resection margin visible on B-mode ultrasound (inside the liver) is considered perilesional tissue and should be evaluated using [Perilesional Tumor Viability](#) criteria.
 - In patients after partial hepatectomy, the entire resection margin is considered perilesional parenchyma.
- In patients after **small focal segmental or wedge resections**, a surgical cavity is often visible on B-mode ultrasound:
 - Resection cavities visible on B-mode are evaluated using [Intralesional Tumor Viability](#) criteria.
 - Resection cavities should demonstrate no internal enhancement in patients with no viable disease.
 - Viable disease should show masslike enhancement.
- In patients after **large segmental resections or lobectomies** without surgical cavity visible on B-mode ultrasound:
 - Intralesional Tumor Viability should be applied with caution, and is generally labeled as “Absent”.
 - Viable disease should have a convincing B-mode correlate.

Are there any pitfalls in assessing treatment response after surgical resection?

Yes. There is limited literature on CEUS treatment response assessment of surgical resection at this time.

LI-RADS CEUS TRA should not be applied or applied with caution in patients if the surgical cavity is not clearly visible on B-mode US or when the entire surgical margin can not be clearly visualized with B-mode ultrasound. In these cases, evaluation with an alternative imaging modality is advised.

Similar to other non-radiation LRTs, granulation tissue along the surgical cavity margin could demonstrate mild hypoenhancement. This uncommon appearance should not be confused with Intralesional Tumor Viability.

Extrahepatic structures, such as omentum or bowel, might fill the resection cavity and result in variable post-contrast enhancement on CEUS. This should not be confused with intralesional tumor viability. If differentiation is difficult, consider evaluation with an alternative imaging modality.



Abbreviations

ACR	American College of Radiology
AP	Arterial phase
APHE	Arterial phase hyperenhancement
CEUS	Contrast-enhanced ultrasound
cTACE	Transarterial chemo-embolization
cHCC-CCA	Combined hepatocellular-cholangiocarcinoma
DEB-TACE	Drug-eluting beads TACE
EASL	European Association for the Study of Liver Disease
HCC	Hepatocellular carcinoma
iCCA	Intrahepatic cholangiocarcinoma
LI-RADS	Liver Imaging Reporting and Data System
LRT	Locoregional therapy
mRECIST	Modified RECIST
MDD	Multidisciplinary discussion
MWA	Microwave ablation
Non-RT	Nonradiation
PEA	Percutaneous ethanol ablation
RECIST	Response Evaluation Criteria in Solid Tumors
RFA	Radiofrequency ablation
SBRT	Stereotactic body radiation therapy
TAE	Transarterial (bland) embolization
TARE	⁹⁰ Y Transarterial radioembolization
TR	Treatment response
TRA	Treatment response assessment
US	Ultrasound



Authors

Lead authors

Andrej Lyshchik, MD, PhD
David T. Fetzer, MD

Contrast-enhanced ultrasound WG

Members

Dirk Clevert, MD, PhD
Christoph F. Dietrich , MD, PhD
David T. Fetzer, MD
Hyun-Jung Jang, MD, PhD
Tae Kyoung Kim, MD, PhD
Masatoshi Kudo, MD, PhD
Jeong Min Lee, MD, PhD
Andrej Lyshchik , MD, PhD
Franca Meloni, MD
Yasunori Minami, MD, PhD
Fabio Piscaglia , MD
Claude Sirlin, MD
Stephanie R. Wilson, MD



Acknowledgements

The LI-RADS Treatment Response Working Group would like to acknowledge the LI-RADS Lexicon and the LI-RADS Steering Committee for their critical review of this document.

Lexicon & Writing Group

Chairs

An Tang, MD

Claude Sirlin, MD

Members

Mustafa Bashir, MD

Victoria Chernyak, MD

Guilherme Cunha, MD

David Fetzer, MD

Kathryn Fowler, MD

Aya Kamaya, MD

Jimmy Lee, MD

Matt McInnes, MD

Mishal Mendiratta-Lala, MD

Sedighe Shabanani, MD

Amit Singal, MD

Treatment Response WG

Chair

Mishal Mendiratta Lala, MD

Members

Mustafa Bashir, MD

Resmi Charalel, MD

Ahmed Gabr, MD

Kathryn Fowler, MD

Avinash Kambadakone, MD

Ania Kielar, MD

Charles Kim, MD

Robert Lewandowski, MD

Sara Lewis, MD

David C. Madoff, MD

Frank Miller, MD

Amit Singal, MD

Anuradha Shenoy-Bhangle, MD

Bradley Spieler, MD

Joseph Yacoub, MD

Vahid Yaghani, MD

Hooman Yarmohammadi, MD

Takeshi Yokoo, MD

Steering Committee

Chairs

Victoria Chernyak, MD

Kathryn Fowler, MD

Members

Mustafa Bashir, MD

Jason Birnbaum, MD

Amir Borhani, MD

Ryan Brunsing, MD

Guilherme Cunha, MD

David Fetzer, MD

Alice Fung, MD

William Hong, MD

Melina Hosseini, MD

Elizabeth Hecht, MD

Reena Jha, MD

Aya Kamaya, MD

Geetika Khanna, MD

Andrea Siobhan Kierans, MD

Jimmy Lee, MD

Andrej Lyshchik, MD

Robert Marks, MD

Matt McInnes, MD

Mishal Mendiratta-Lala, MD

Donald Mitchell, MD

Shuchi Rodgers, MD

Maxime Ronot, MD

Alexandra Roudenko, MD

Anthony Samir, MD

Cynthia Santillan, MD

Sedighe Shabanani, MD

Amit Singal, MD

Claude Sirlin, MD

An Tang, MD

Lisa VanWagner, MD

Sudhakar Venkatesh, MD

Takeshi Yokoo, MD, PhD



Acknowledgements

Figures in this documents are used in part with permission of RSNA, from “Contrast-Enhanced US Liver Imaging Reporting and Data System Treatment Response Algorithm”, A. Lyshchik et al, Radiology 2024; permission conveyed through Copyright Clearance Center, Inc
