

Valvular Heart Disease in Pergolide-Treated Parkinson's Disease

James Scozzafava, Jennifer Takahashi, Wendy Johnston, Lakshmi Puttagunta, W.R. Wayne Martin

ABSTRACT: Background: A 61-year-old woman with Parkinson's disease, receiving pergolide 1.75 mg four times daily, was admitted with progressive dyspnea. **Methods:** Investigations revealed mitral and aortic regurgitation. She underwent surgical mitral replacement and aortic repair, but had a post-operative course characterized by repeated bouts of congestive heart failure. **Results:** Severe tricuspid valve (TV) regurgitation developed within one month after the TV was reported on echocardiography to be relatively normal. Subsequent discontinuation of pergolide was associated with symptomatic improvement. **Conclusions:** This case illustrates the severity and rapidity with which cardiac valvular abnormalities can develop in patients receiving pergolide.

RÉSUMÉ: Valvulopathie cardiaque chez une parkinsonienne sous pergolide. Contexte: Une femme âgée de 61 ans, traitée avec du pergolide 1,75 mg quatre fois par jour pour une maladie de Parkinson, a été hospitalisée pour dyspnée progressive. **Méthodes:** L'évaluation de la patiente a mis en évidence une régurgitation mitrale et aortique. Elle a subi un remplacement mitral et une réfection aortique. Au cours des suites opératoires, elle a présenté des épisodes d'insuffisance cardiaque à répétition. **Résultats:** Bien que le rapport d'échographie ait fait état d'une tricuspide relativement normale un mois auparavant, on a constaté subséquemment une régurgitation tricuspiddienne sévère. Les symptômes ont régressé à l'arrêt du pergolide. **Conclusions:** Cette observation illustre la sévérité et la rapidité d'installation de la valvulopathie cardiaque chez les patients sous pergolide.

Can. J. Neurol. Sci. 2006; 33:111-113

Pergolide is an ergot-derived dopamine agonist used in the treatment of Parkinson's disease (PD). Like other ergot derivatives, pergolide can be associated with fibrotic complications, including cardiac valvulopathy. Recent reports have indicated that these valvular changes may occur more commonly than initially recognized. The present case demonstrates how rapidly these changes can evolve in the setting of pergolide treatment.

CASE REPORT

A 61-year-old woman was admitted with a one year history of progressive dyspnea. There was no previous history of heart disease or other significant medical problems, except for PD diagnosed about seven years previously. At that time she was started on levodopa/carbidopa, which produced good symptom control for about three years, until end-of-dose deterioration developed. Pergolide was added and proved successful in regaining control of her Parkinson's symptoms. Parkinson's disease medications at the time of hospital admission consisted of controlled release levodopa/carbidopa 200/50, 1.5 tablets four times daily, and pergolide 1.75mg four times daily.

Examination revealed a thin, anxious woman with signs of congestive heart failure, including a Grade III/VI pansystolic murmur

involving the entire precordium, and evidence of pulmonary and peripheral edema. There was mild symmetrical cogwheel rigidity in upper limbs, slight resting tremor of both hands, and bradykinesia for repetitive finger movements. In general, PD signs seemed well controlled.

Cardiac investigations included transesophageal echocardiogram (TEE), which confirmed the presence of severe mitral valve (MV) regurgitation and moderate aortic valve (AV) insufficiency. The pulmonary and tricuspid valves (TV) were relatively normal, although mild TV regurgitation was noted. Surgical AV repair and MV replacement were undertaken, with the MV replaced by a mosaic bioprosthetic tissue valve. Intra-operatively, significant thickening of all

From the Division of Neurology (JS, JT, WJ, WRWM), Department of Laboratory Medicine and Pathology (LP), University of Alberta, Edmonton, Alberta, Canada.

RECEIVED SEPTEMBER 21, 2005. ACCEPTED IN FINAL FORM DECEMBER 12, 2005.
Reprint requests to: W.R.W. Martin, Movement Disorders Clinic, Glenrose Rehabilitation Hospital, 10230-111 Avenue, Edmonton, Alberta, T5G 0B7, Canada.

MV and AV leaflets, as well as thickening and shortening of the chordae, was evident. Pathology showed fibrotic and focal myxoid degenerative changes of the leaflets of both valves, with no evidence of vegetation or calcification (Fig 1A and 1B). Investigations pursuing a possible carcinoid source revealed no relevant abnormalities.

The patient improved post-operatively and was discharged the following week, continuing on the same PD medications. She was re-admitted shortly afterward with acute sepsis, acute renal failure (ARF) and congestive heart failure (CHF), including large pleural and peritoneal effusions. Transthoracic echocardiogram now revealed moderate TV regurgitation, mild MV regurgitation, and a 2-3 mm periprosthetic leak. No valve vegetations were seen. The patient improved with medical treatment and was transferred to a hospital closer to her home. She returned ten days later, however, with increasing CHF and recurrent pleural effusion. Transesophageal echocardiogram now showed severe TV regurgitation. Left ventricular ejection fraction (LVEF) was 40-45%. No significant change to the remaining valves was noted; there was no evidence to suggest endocarditis on TEE or blood cultures. She was again managed medically with aggressive diuresis and improved symptomatically and radiologically. She was discharged home one week later.

She was re-admitted a short time later, approximately one month after her original admission, with severe CHF and ARF, complicated by urosepsis, acute respiratory distress, and delirium. At that time, TEE revealed in addition to severe TV regurgitation, mild-moderate MV regurgitation and moderate AV regurgitation. The actual tricuspid valve architecture and position of annulus were normal. There was no evidence of infective endocarditis or other possible precipitants to account for this patient's recurrent valvular and congestive heart disease.

At this time, the Neurology Service was consulted regarding the delirium and the possibility that pergolide may be contributing to her worsening cardiac and neurological condition. Pergolide was gradually withdrawn over several weeks and the CHF symptoms improved. She was discharged home several weeks later and remained out of hospital without any subsequent episodes of CHF or evidence of worsening cardiac function. A repeat echocardiogram several months after the withdrawal of pergolide showed improvement in function of all valves, particularly the aortic and tricuspid valves. Furthermore, pulmonary artery pressure had improved to 30 mmHg and left ventricular ejection fraction was greater than 75% without any wall motion abnormalities. Some mild to moderate regurgitation of the previously diseased valves remained.

DISCUSSION

This patient developed severe cardiac valvular disease, in the absence of any significant preceding heart disease, while receiving a high dose of pergolide. Valvular dysfunction progressed rapidly, initially involving the MV and AV. The TV, first described as relatively normal on echocardiogram, became severely and progressively impaired within four weeks. The presentation, including the histological changes in MV and AV leaflets, was most consistent with carcinoid-like valve disease associated with pergolide treatment. Although left with a permanent deficit in cardiac function, the patient's symptomatic improvement in cardiac status during decreasing doses of pergolide supports the clinical impression that high doses of pergolide may have been the major cause of her progressive valvular heart disease.

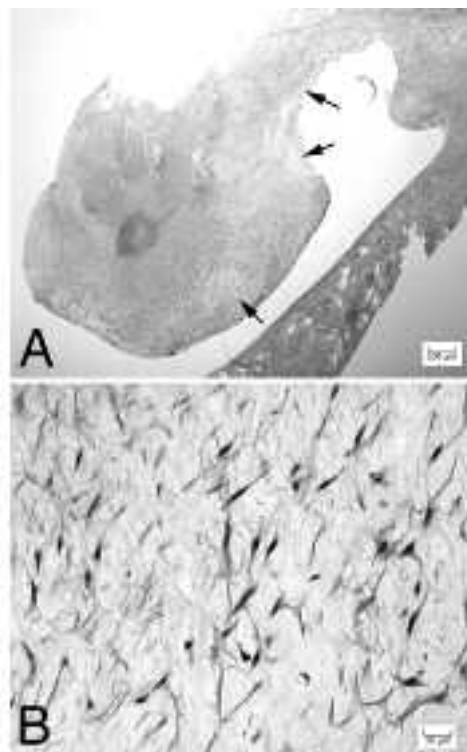


Figure : 1A) Low magnification view of cardiac valve leaflet with regions of myxoid degeneration (arrows). Hematoxylin and eosin. 1B) High magnification of an area of myxoid degeneration with scattered stellate cells. Hematoxylin and eosin.

Several drugs have been associated with valvular heart disease, particularly with carcinoid-like appearances, the first reports appearing in 1966.^{1,2} By the 1990's, numerous reports had emerged describing carcinoid-like valvular heart disease associated with 5-HT₂ preferring ergot derivatives, with the most attention received by the appetite suppressant fenfluramine.^{3,4} Fitzgerald and colleagues⁵ proposed that preferential stimulation of valvular 5-HT_{2B} receptors by the metabolite norfenfluramine might induce mitogenic activities involved in cell proliferation, producing valvular fibroplasia.

Recently, concern has emerged regarding similar valve changes with ergot-derived PD medications. Fibrotic multi-valvular disease, including severe TV regurgitation, was reported in a patient who had received bromocriptine for five years.⁶ Three cases, with very similar presentations, strongly suggested an association between pergolide and valvular pathology.⁷ These patients had TV disease involving plaque-like thickening of the leaflets, cords and papillary muscles as well as similar left sided valvular disease; pathology was similar to that described in ergotamine and methysergide-induced valvular heart disease.⁷

More recently, similar changes were described, involving both TV and MV, as well as the AV, in PD patients taking more than 5 mg pergolide per day.⁸ These authors subsequently suggested that up to 33% of patients receiving pergolide may have some degree of restrictive valvular disease.⁹ Baseman et

al¹⁰ suggested an even higher prevalence, with 89% of pergolide-treated patients having some degree of valvular insufficiency.

This group reported a 2- to 3-fold increased risk of abnormal valves in pergolide-treated patients, and an estimated 14-fold increased risk of tricuspid regurgitation. The mechanism whereby pergolide may induce valvular lesions is unknown, but it is noteworthy that agonist properties at 5-HT receptors have been reported,¹¹ suggesting a similarity to other ergot derivatives such as fenfluramine.

Our observations support the postulated relationship between pergolide and cardiac valvular disease. They illustrate not only the potential severity of this complication, but also the rapidity with which the valvular changes can develop in patients receiving pergolide. These findings urge the cautious use of this medication and encourage further study into the association between ergot derivatives and valvular heart disease.

ACKNOWLEDGEMENTS

The authors thank Tom Turner and Allen McLean for their assistance, and Dr. Richard Camicioli for his support and advice.

REFERENCES

- Graham JR, Suby HI, LeCompte PR, Sadowsky NL. Fibrotic disorders associated with methysergide therapy for headache. *N Engl J Med.* 1966;274:359-68.
- Misch KA. Development of heart valve lesions during methysergide therapy. *Br Med J.* 1974;2:365-6.
- Connolly HM, Crary JL, McGoon MD, et al. Valvular heart disease associated with fenfluramine-phentermine. *N Engl J Med.* 1997;337:581-8.
- Khan MA, Herzog CA, St. Peter JV, et al. The prevalence of cardiac valvular insufficiency assessed by transthoracic echocardiography in obese patients treated with appetite-suppressant drugs. *N Engl J Med.* 1998;339: 713-8.
- Fitzgerald LW, Burn TC, Brown BS, et al. Possible role of valvular serotonin 5-HT_{2B} receptors in the cardiopathy associated with fenfluramine. *Mol Pharmacol.* 2000;57:75-81.
- Serratrice J, Disdier P, Habib G, Viallet F, Weiller P. Fibrotic valvular heart disease subsequent to bromocriptine treatment. *Cardiol Rev.* 2002;10:334-6.
- Pritchett A, Morrison J, Edwards W, et al. Valvular heart disease in patients taking pergolide. *Mayo Clin Proc.* 2002;77:1280-6.
- Van Camp G, Flamez A, Cosyns B, et al. Heart valvular disease in patients with Parkinson's disease treated with high-dose pergolide. *Neurology.* 2003;61:859-61.
- Van Camp G, Flamez A, Cosyns B, et al. Treatment of Parkinson's disease with pergolide and relation to restrictive valvular heart disease. *Lancet* 2004;363:1179-83.
- Baseman DG, O'Suilleabhain PE, Reimold SC, Laskar SR, Baseman JG, Dewey RB. Pergolide use in Parkinson disease is associated with cardiac valve regurgitation. *Neurology.* 2004;63:301-4.
- Boess FG, Martin IL. Molecular biology of 5-HT receptors. *Neuropharmacology.* 1994;33:275-317.