

# Common Interventional Pain Procedures

**PAIN INTERVENTION FUNDAMENTALS..... page 2**

**SPINAL INJECTIONS & INTERVENTIONS ..... page 4**

- 1. Interlaminar Epidural Glucocorticoid Injection (Lumbar/Cervical) ..... page 5
- 2. Transforaminal Epidural Glucocorticoid Injection (Lumbar) ..... page 6
- 3. Facet Injection/Medial Branch Block (Cervical, Thoracic, or Lumbar) ..... page 7
- 4. Radiofrequency Lesioning/Neurotomy (Lumbar/Cervical) ..... page 8
- 5. Sacroiliac Joint Injection ..... page 9

**SYMPATHETIC NERVE BLOCKS..... page 10**

- 6. Stellate Ganglion Block ..... page 11
- 7. Celiac Plexus Block (With or Without Neurolysis) ..... page 12
- 8. Lumbar Sympathetic Block ..... page 13

**HEAD AND NECK NERVE BLOCKS..... page 14**

- 9. Occipital Nerve Block..... page 15
- 10. Trigeminal Nerve Block..... page 16

**PERIPHERAL NERVE BLOCKS ..... page 18**

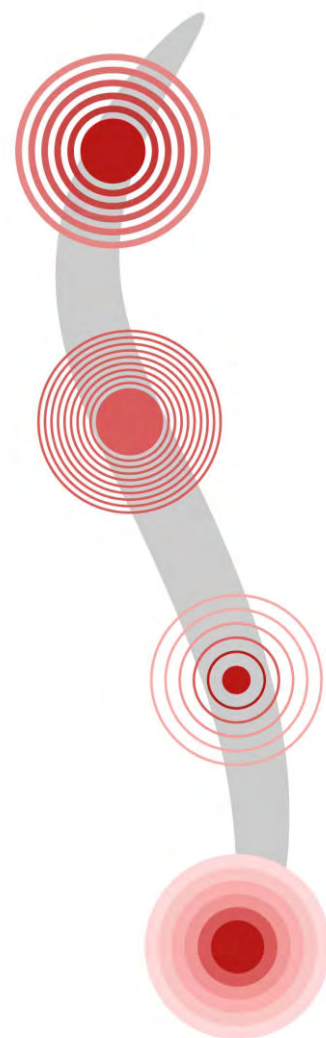
- 11. Ilioinguinal Nerve Block..... page 19
- 12. Lateral Femoral Cutaneous Nerve Block..... page 20
- 13. Pudendal Nerve Block..... page 21
- 14. Genicular Nerve Block..... page 22

**DRY NEEDLING AND TRIGGER POINT INJECTIONS..... page 24**

- 15. Dry Needling and Trigger Point Injections..... page 24

**SURGICAL PAIN MANAGEMENT..... page 25**

- 16. Intrathecal Drug Delivery ..... page 26
- 17. Neuromodulation (Spinal Cord Stimulation)..... page 27
- 18. Neuromodulation (Peripheral Nerve Stimulation) ..... page 28



## COMMON INTERVENTIONAL PAIN PROCEDURES

A range of interventional procedures for pain can be useful in patients with chronic pain who have not achieved adequate relief with conservative treatments. Typically, given the invasive nature of these procedures, they are not first-line treatments for pain. Instead, they are considered only after failure to achieve pain relief with adequate trials of medication, at least 6 weeks of physical therapy, or both.

More than 200 interventional procedures are routinely performed, most often by clinicians who have received additional fellowship-level training. The types of procedures range from simple peripheral nerve blocks to spinal interventions to more-invasive surgical procedures that involve implantation of devices. In each subsection below, the most common interventions are outlined.

### PAIN INTERVENTION FUNDAMENTALS

Most interventional pain procedures do not require intravenous access unless the patient has a known history of vasovagal syncope; nor do they require sedation unless the patient is very anxious. Most interventional procedures for pain involve injecting a local anesthetic, such as lidocaine or bupivacaine, combined with a glucocorticoid, such as methylprednisolone or dexamethasone. The local anesthetic provides rapid pain relief; the addition of a glucocorticoid enhances longer-term therapeutic efficacy, given the antiinflammatory property of glucocorticoids.

Injection of a local anesthetic alone can be done, typically when the sole goal of the procedure is temporary reduction of pain conduction. This may be the case in a diagnostic block, performed to confirm the analgesic benefit before implementation of more-invasive interventions such as radiofrequency ablation. Another use of local anesthetic alone is in patients for whom glucocorticoids are relatively contraindicated; some studies have shown, in certain pain conditions such as lumbar stenosis, equal efficacy with local anesthetic alone, compared to a local anesthetic combined with glucocorticoids.

Another broad category of interventional pain procedures are ablation procedures, whereby the conduction of pain signals is interrupted through destruction of the nerves, typically

using thermal or chemical ablation. These procedures provide longer-term benefit but are more invasive than injections of a local anesthetic with or without a glucocorticoid.

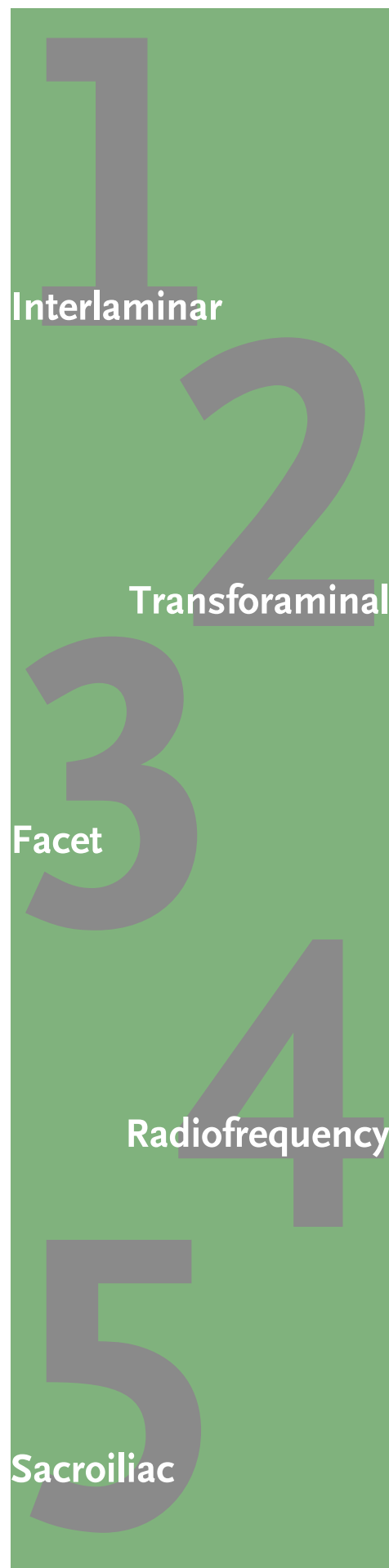**Complications of interventional pain procedures.** Complications are rare and are discussed below with each procedure, but some general considerations are worth highlighting:

- Infection is sufficiently rare that prophylactic antibiotics are rarely used.
- Adverse effects of local anesthetics are usually temporary and include dizziness, headaches, blurred vision, muscle twitching, and localized numbness, tingling, or weakness. An allergic reaction to the local anesthetic or a serious adverse effect such as a seizure or cardiac arrest is very rare.
- If a glucocorticoid is used, the patient is at risk for systemic glucocorticoid exposure with resulting adverse effects (e.g., hyperglycemia, suppression of the hypothalamic–pituitary–adrenal axis, and cushingoid features), especially with repeated injections.
- Vessel occlusion with resulting ischemia also can occur in the case of inadvertent intravascular injection, especially with particulate glucocorticoid solutions such as methylprednisolone or triamcinolone.

**Contraindications to interventional pain procedures.** Contraindications are common among most of the interventions outlined below. They include:

- Active systemic infection or infection of the skin overlying the area where the needle will enter
- Anticoagulation or problems with coagulation. This is especially important with neuraxial procedures, as hemorrhage can lead to irreversible neurologic damage. It is of less concern with peripheral or joint injections (including facet joint injections of the spine), as the risk for nerve compression is low. Anticoagulants should be stopped for a period of time before the procedure, sufficiently adequate to reverse the anticoagulant state. This step is necessary for most anticoagulants, including direct oral anticoagulants and warfarin. For patients taking warfarin, INR should be measured on the day of the procedure. Antiplatelet agents such as P2Y<sub>12</sub> inhibitors (e.g., clopidogrel, prasugrel, ticagrelor) are also stopped before these procedures. Low-dose aspirin and nonsteroidal antiinflammatory drugs carry a low risk for bleeding and typically do not need to be stopped before these procedures.
- Hypersensitivity to glucocorticoids, contrast dye, or anesthetic medications
- Local malignancy at the site of injection
- Special considerations should be made in patients with uncontrolled diabetes (injection with local anesthetic alone may be considered), heart failure, pregnancy (fluoroscopy is contraindicated but ultrasound guidance can be used) — and in patients with cardiac device implantation, in cases of radiofrequency ablation (defibrillator may need to be turned off during the ablation process).

# SPINAL INJECTIONS & INTERVENTIONS



Nearly every adult experiences back pain at some point during their lives, but most episodes resolve spontaneously. In approximately 10% of people, pain persists despite conservative measures and results in significant individual disability and societal cost; within this subgroup, interventional therapies can be considered as treatments for both axial and radicular back pain.

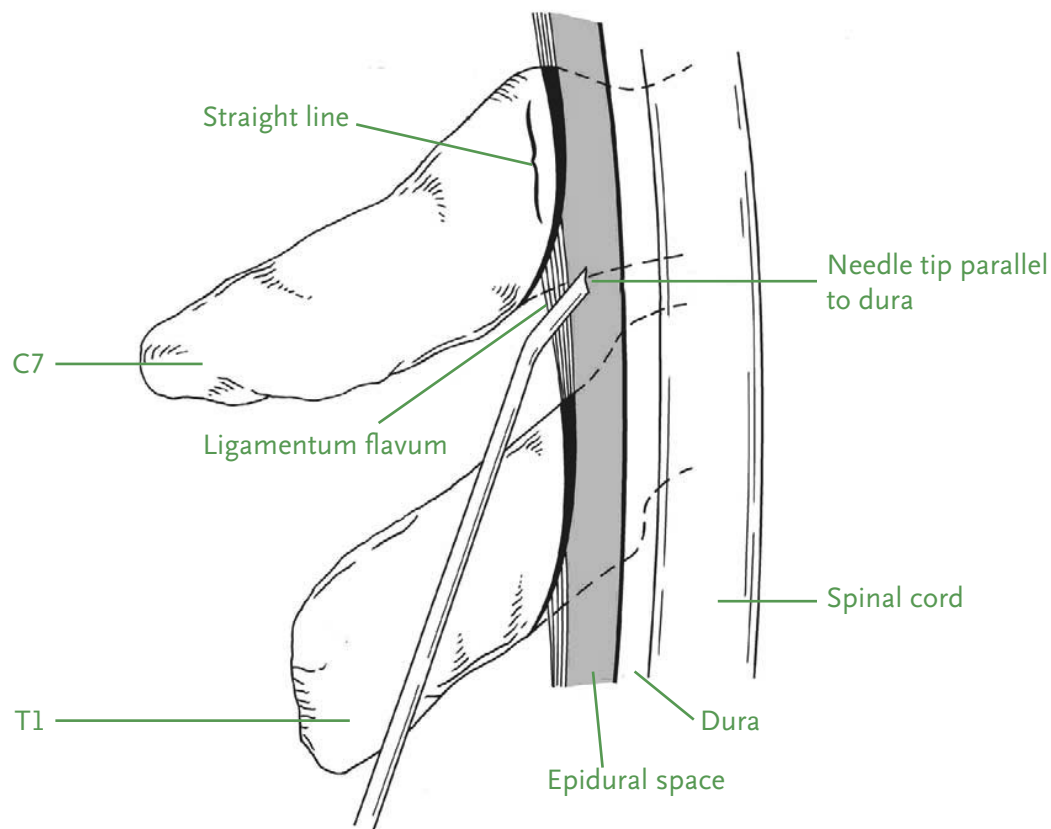
Glucocorticoid injections (first described in 1953 and commonly referred to as epidural steroid injections) are the first-line invasive procedure for treating spine-generated pain. Despite widespread use of these injections, controversy remains about their efficacy and uncertainty remains about the mechanism of therapeutic benefit. Several mechanisms have been proposed, including antiinflammatory effects, direct neural membrane stabilization effects, and modulation of peripheral nociceptor input. The vast majority of patients who respond favorably do so within 6 days of injection.

A lumbar MRI is strongly recommended before these neuraxial procedures, to help determine the point of interest for the injection and to rule out conditions that are considered to be contraindications, such as diskitis or epidural fluid collections. The desired site of injection is also determined through physical examination (to identify dermatomal distribution) and, occasionally, neurophysiological studies. Injection of contrast medium is strongly recommended to confirm correct needle placement.

In addition to various approaches for performing epidural glucocorticoid injections, there are other interventional procedures that are used in the management of back pain. The patient's history, physical examination, and MRI findings — as well as the expertise and experience of the clinician performing the procedure — all help to determine the best procedure for any given scenario.

# SPINAL INJECTIONS & INTERVENTIONS

## Interlaminar Epidural Glucocorticoid Injection (Lumbar/Cervical)



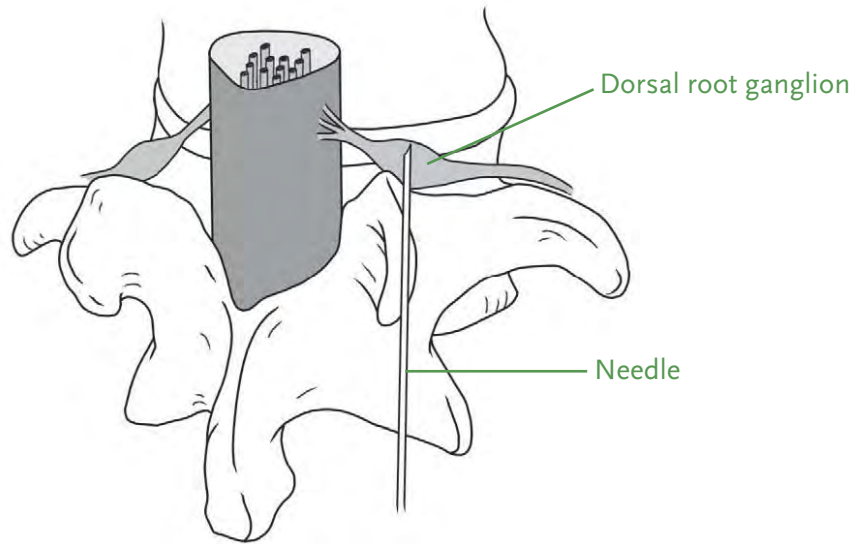
INDICATIONS	POTENTIAL COMPLICATIONS	CLINICAL PEARLS	HOW TO PERFORM
<ul style="list-style-type: none"> <li>■ Lumbar/cervical radiculopathy</li> <li>■ Lumbar/cervical stenosis</li> <li>■ Lumbar/cervical disk herniation without myelopathy</li> </ul>	<ul style="list-style-type: none"> <li>■ Epidural bleeding or hematoma</li> <li>■ Local infection, including epidural abscess, which can compress nerve roots or the spinal cord and lead to a radiculopathy or myelopathy</li> <li>■ Direct spinal cord trauma</li> <li>■ Dural puncture, leading to injection of medications into the subarachnoid space with adverse effects such as high spinal anesthesia and respiratory depression</li> </ul>	<ul style="list-style-type: none"> <li>■ Prepare the patient that they may receive one injection or a series of three injections (typically 4 weeks apart), depending on their response</li> <li>■ Limit injections to 4 to 6 per year, typically 3 months apart after the first series.</li> <li>■ Commonly used glucocorticoids are methylprednisolone or dexamethasone.</li> </ul>	<ul style="list-style-type: none"> <li>■ A small needle is placed into the epidural space through the midline under fluoroscopic guidance.</li> <li>■ Once the needle is in position, 3 to 5 cc of the injectate is administered slowly, to prevent acute compression of the nerves or spinal cord.</li> </ul>

### References:

1. Friedly JL et al. A randomized trial of epidural glucocorticoid injections for spinal stenosis. *N Engl J Med* 2014; 371:11.
2. Chang-Chien GC et al. Transforaminal versus interlaminar approaches to epidural steroid injections: A systematic review of comparative studies for lumbosacral radicular pain. *Pain Physician* 2014; 17:E509.

# SPINAL INJECTIONS & INTERVENTIONS

## 2 Transforaminal Epidural Glucocorticoid Injection (Lumbar)



Final needle position for a lumbar transforaminal injection

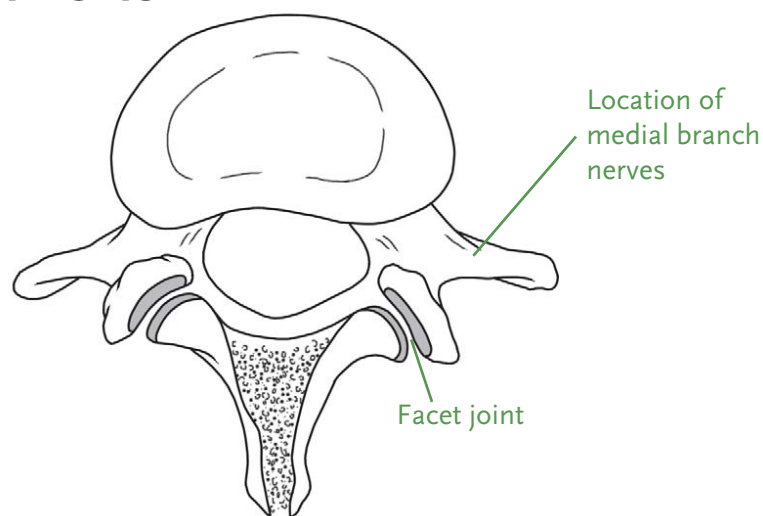
INDICATIONS	POTENTIAL COMPLICATIONS	CLINICAL PEARLS	HOW TO PERFORM
<ul style="list-style-type: none"> <li>■ Lumbar radiculopathy</li> <li>■ Lumbar stenosis</li> <li>■ Lumbar disk herniation without myelopathy</li> </ul>	<ul style="list-style-type: none"> <li>■ Epidural bleeding or hematoma</li> <li>■ Local infection, including epidural abscess, which can compress nerve roots or the spinal cord and lead to a radiculopathy or myelopathy</li> <li>■ Direct spinal cord or nerve trauma</li> <li>■ Dural puncture, leading to injection of medications into the subarachnoid space with adverse effects such as high spinal anesthesia and respiratory depression</li> </ul>	<ul style="list-style-type: none"> <li>■ Dexamethasone is commonly used, given reports of catastrophic neurologic injury with particulate glucocorticoid solutions.</li> <li>■ In unilateral radiculopathy, the transforaminal or interlaminar approaches are equally effective in reducing pain and improving function; the choice usually depends on clinician preference and experience.</li> <li>■ In bilateral radiculopathy, the interlaminar approach is preferable, as a single injection can affect both sides, while transforaminal injections would need to be done on both sides.</li> </ul>	<ul style="list-style-type: none"> <li>■ A small needle is placed into the epidural space lateral to the midline (allowing some of the injectate to spread along the nerve, thereby providing a selective nerve block at the same time). Fluoroscopic guidance is used.</li> <li>■ Once the position is confirmed, 1 to 2 mL of the injectate is administered slowly, to prevent nerve compression.</li> </ul>

**References:**

1. Ghahreman A et al. The efficacy of transforaminal injection of steroids for the treatment of lumbar radicular pain. *Pain Med* 2010; 11:1149.
2. Buenaventura RM et al. Systematic review of therapeutic lumbar transforaminal epidural steroid injections. *Pain Physician* 2009; 12:233.

# SPINAL INJECTIONS & INTERVENTIONS

## Facet Injection/ Medial Branch Block (Cervical, Thoracic, or Lumbar)



Axial view of an L3-L4 joint, showing the location of the facet joints and medial branch nerves. I, inferior articular process of L3. S, superior articular facet L4.

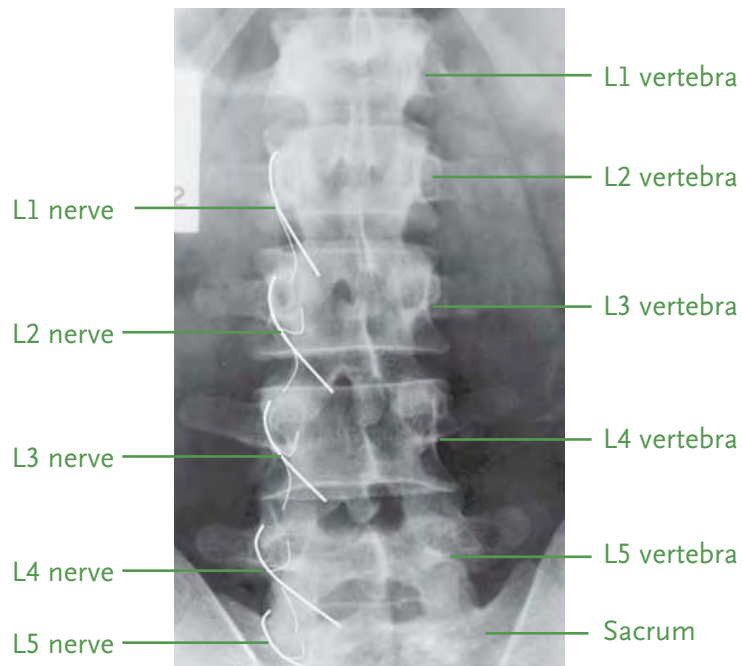
INDICATIONS	POTENTIAL COMPLICATIONS	CLINICAL PEARLS	HOW TO PERFORM
<ul style="list-style-type: none"> <li>■ Spondylosis</li> <li>■ Facet arthropathy</li> <li>■ Postlaminectomy syndrome</li> <li>■ Disk degeneration</li> </ul>	<ul style="list-style-type: none"> <li>■ Epidural bleeding or hematoma</li> <li>■ Local infection, including epidural abscess, which can compress nerve roots or the spinal cord and lead to a radiculopathy or myelopathy.</li> <li>■ Direct spinal cord or nerve trauma</li> <li>■ Dural puncture, leading to injection of medications into the subarachnoid space with adverse effects such as high spinal anesthesia and respiratory depression</li> </ul>	<ul style="list-style-type: none"> <li>■ The triad of axial neck pain, muscle spasms, and posterior headaches often points to cervical facet arthropathy.</li> <li>■ Diagnostic medial branch blocks to determine candidacy for radiofrequency ablation should use low volumes, to reduce confounding spread to adjacent structures.</li> <li>■ Glucocorticoids are typically used in the injectate to prolong pain relief. However, diagnostic blocks prior to radiofrequency ablation are done with a local anesthetic.</li> <li>■ Some patients elect to get therapeutic medial branch blocks every 3 months rather than proceed to radiofrequency ablation.</li> </ul>	<ul style="list-style-type: none"> <li>■ A spinal needle is placed into the area of the facet joints or the medial branch nerves, under fluoroscopic guidance.</li> <li>■ Once in position, 0.5 to 1.0 mL of the injectate is administered at the target site.</li> </ul>

### References:

1. Falco FJ et al. Systematic review of the therapeutic effectiveness of cervical facet joint interventions: An update. *Pain Physician* 2012; 15:E839.
2. Patel VB and Data S. Chapter 23: Facet joint Interventions: Intra-articular injections, medial branch blocks, and radiofrequency ablations. In: *Atlas of pain medicine procedures*. New York: McGraw-Hill Education; 2015.

# SPINAL INJECTIONS & INTERVENTIONS

## Radiofrequency Lesioning/ Neurotomy (Lumbar/Cervical)



Medial branch anatomy, showing the curve of the medial branches of the lumbar dorsal rami (left) with articular branches to the facet joints

INDICATIONS	POTENTIAL COMPLICATIONS	CLINICAL PEARLS	HOW TO PERFORM
<ul style="list-style-type: none"> <li>Significant pain relief (&gt;50%) after diagnostic medial branch blocks</li> </ul>	<ul style="list-style-type: none"> <li>Postprocedural pain</li> <li>Cutaneous numbness</li> <li>Dysesthesias</li> <li>Dizziness and ataxia (with cervical radiofrequency lesioning)</li> <li>Infection</li> <li>Nerve or vascular Injury (rare)</li> </ul>	<ul style="list-style-type: none"> <li>Prior to ablation, perform at least 2 rounds of medial branch blocks to determine the likelihood of response to ablation.</li> <li>The average duration of &gt;50% pain relief for radiofrequency neurotomy is 6 to 12 months.</li> </ul>	<ul style="list-style-type: none"> <li>A 22-g or 18-g radiofrequency needle is placed into the area of the facet joints along the medial branches under fluoroscopic guidance.</li> <li>Sensory and motor stimulation are usually performed before denervation, to ensure proper positioning of the needles close to the target areas and away from the motor fibers.</li> <li>A small amount of local anesthetic (typically lidocaine 2%) is injected first. Denervation is then achieved using radiofrequency thermal ablation.</li> </ul>

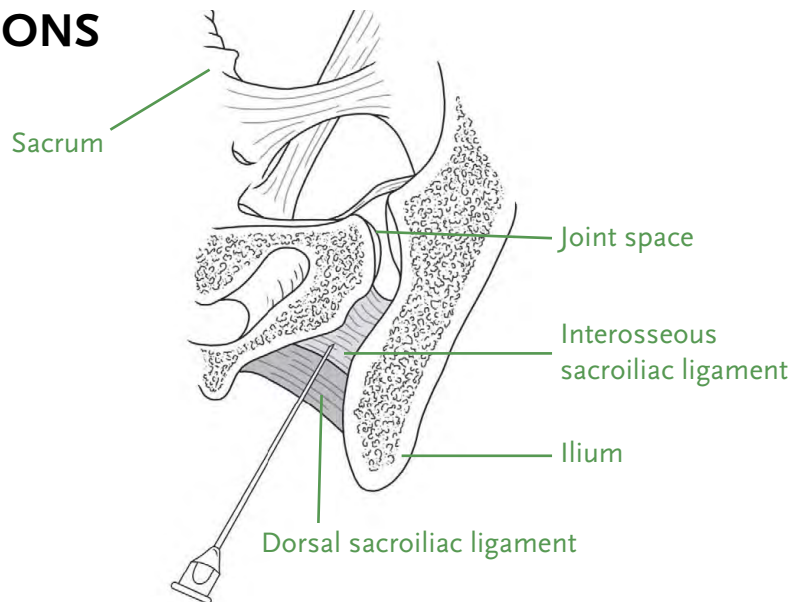
### References:

- MacVicar J et al. Lumbar medial branch radiofrequency neurotomy in New Zealand. *Pain Med* 2013; 14:639.
- Schofferman J and Kine G. Effectiveness of repeated radiofrequency neurotomy for lumbar facet pain. *Spine* 2004; 29:2471.



# SPINAL INJECTIONS & INTERVENTIONS

## Sacroiliac Joint Injection



Cross section of the sacroiliac joint showing the entry of the needle at the dorsal inferior aspect of the joint.

INDICATIONS	POTENTIAL COMPLICATIONS	CLINICAL PEARLS	HOW TO PERFORM
<ul style="list-style-type: none"> <li>■ Sacroiliac (SI) joint pain</li> <li>■ SI joint inflammation</li> <li>■ SI joint dysfunction</li> </ul>	<ul style="list-style-type: none"> <li>■ Bleeding</li> <li>■ Infection</li> <li>■ Nerve injury</li> <li>■ Transient increased postprocedural pain</li> </ul>	<ul style="list-style-type: none"> <li>■ Diagnostic analgesic blocks in patients with suspected SI joint pain can provide valuable information about pathologies of joint origin, but pain secondary to pathologies in structures around the SI joint can be missed and are best diagnosed with provocation tests.</li> <li>■ A multitest regimen of 3 or more positive SI joint pain provocation tests (distraction, compression, Gaenslen, Patrick, and thigh thrust tests) is a reliable method for assessing SI joint disease.</li> <li>■ Radiofrequency ablation of the SI joint can be considered for patients who receive only temporary relief from diagnostic SI joint injections.</li> </ul>	<ul style="list-style-type: none"> <li>■ A spinal needle is placed along and/or into the sacroiliac joint under fluoroscopic guidance.</li> <li>■ Once correct positioning is confirmed with fluoroscopy, the injectate is administered along or into the SI joint.</li> </ul>

### References:

1. Rupert MP et al. Evaluation of sacroiliac joint interventions: A systematic appraisal of the literature. *Pain Physician* 2009; 12:399.
2. Simopoulos TT et al. A systematic evaluation of prevalence and diagnostic accuracy of sacroiliac joint interventions. *Pain Physician* 2012; 15:E305.

## SYMPATHETIC NERVE BLOCKS

### 6 Stellate Ganglion

**Sympathetic nerve blocks** are effective for treating painful conditions that are thought to be mediated by the sympathetic nervous system. The most common indications for the procedure are complex regional pain syndrome (CRPS) and visceral pain (especially visceral pain associated with cancer). Depending on the pain's location, the sympathetic nerves can be blocked at the stellate ganglion for upper-extremity pain, the lumbar sympathetic ganglion for lower-extremity pain, or the abdomen (celiac, superior, and ganglion impar) for visceral pain.

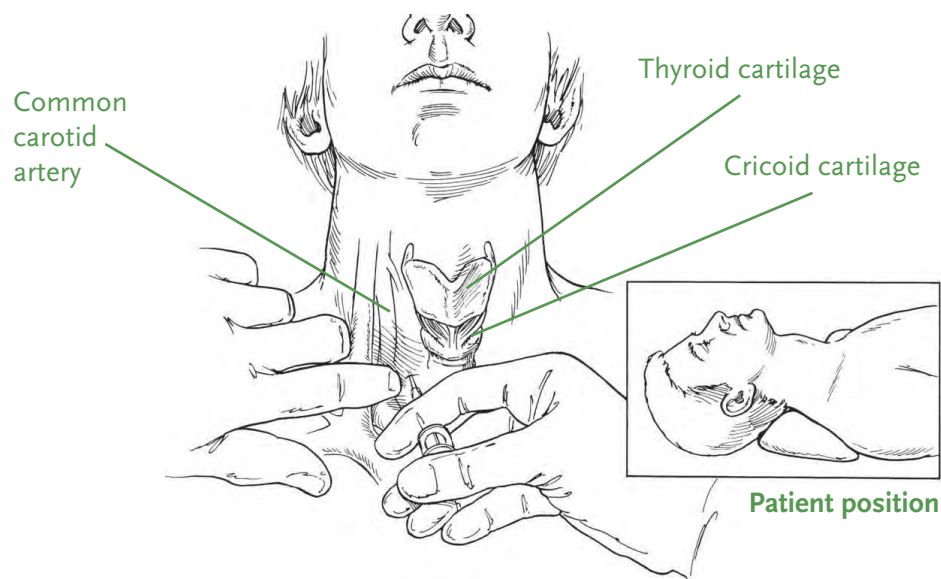
### 7 Celiac Plexus

### 8 Lumbar Sympathetic

# SYMPATHETIC NERVE BLOCKS

## Stellate Ganglion Block

6



Location of needle entry for a stellate ganglion block

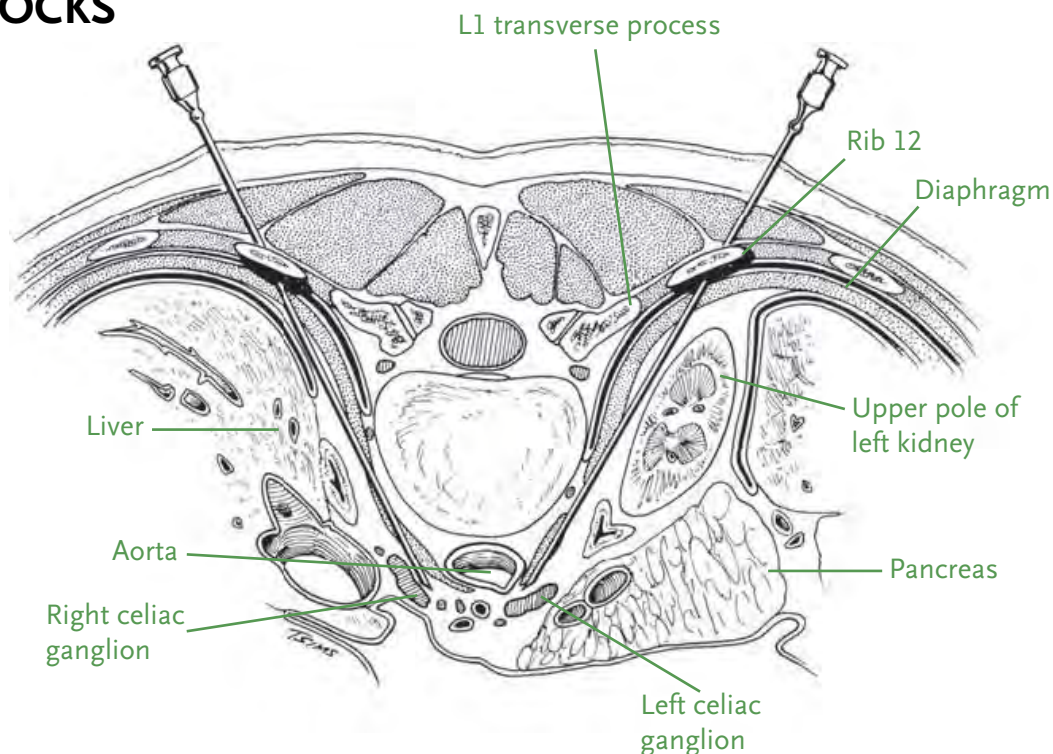
INDICATIONS	POTENTIAL COMPLICATIONS	CLINICAL PEARLS	HOW TO PERFORM
<p><b>Sympathetically mediated painful conditions:</b></p> <ul style="list-style-type: none"> <li>Complex regional pain syndrome (CRPS) type 1 and 2 of the upper extremity</li> <li>Herpes zoster</li> <li>Postherpetic neuralgia</li> <li>Peripheral nerve lesions</li> <li>Phantom limb pain</li> <li>Postmyocardial, sympathetically mediated pain</li> <li>Malignant, sympathetically mediated pain</li> </ul> <p><b>Vascular conditions:</b></p> <ul style="list-style-type: none"> <li>Refractory angina</li> <li>Raynaud disease</li> <li>Peripheral vascular disease</li> </ul> <p><b>Long COVID syndrome</b></p>	<p><b>Vascular injury or hematoma:</b></p> <ul style="list-style-type: none"> <li>Carotid artery, internal jugular vein, inferior thyroid artery</li> <li>Ascending cervical artery</li> <li>Retropharyngeal hematoma</li> </ul> <p><b>Neurological injury:</b></p> <ul style="list-style-type: none"> <li>Vagus nerve, brachial plexus root (C6, C7) injury</li> <li>Locked-in syndrome, stroke</li> <li>Neuraxial injection</li> </ul> <p><b>Others:</b></p> <ul style="list-style-type: none"> <li>Pneumothorax, chylothorax</li> <li>Infection</li> </ul>	<ul style="list-style-type: none"> <li>Although it is considered a side effect, the presence of Horner syndrome is a sign of successful block.</li> <li>Other possible side effects of this block include hoarseness of voice, phrenic nerve block resulting in ipsilateral diaphragmatic paralysis, and brachial plexus block resulting in arm weakness. However, all of these side effects are transient.</li> <li>In CRPS of the upper extremity, if stellate ganglion block provides good but short-term relief, neuromodulation is a reasonable next option to consider.</li> </ul>	<ul style="list-style-type: none"> <li>A needle is placed along the stellate ganglion. Positioning can be guided by anatomic landmarks, fluoroscopy, or ultrasound (most common); a combination of fluoroscopy and ultrasound is sometimes used to increase safety and avoid vascular structures.</li> <li>A small amount of contrast may be used if fluoroscopy is utilized to confirm positioning and to ensure there is no vascular uptake.</li> <li>Once correct positioning is confirmed, 5 to 10 mL of the injectate is administered slowly, in small increments, to ensure there is no systemic spread of the injectate.</li> </ul>

**References:**

- Waldman SD. Ultrasound-guided stellate ganglion block. In: Ultrasound-guided pain management injection techniques, 1st ed. Philadelphia: Lippincott Williams & Wilkins; 2014. pp. 156–62.
- Day M. Sympathetic blocks: The evidence. Pain Pract 2008; 8:98.

# SYMPATHETIC NERVE BLOCKS

## Celiac Plexus Block (With or Without Neurolysis)



Cross section of celiac plexus block

INDICATIONS	POTENTIAL COMPLICATIONS	CLINICAL PEARLS
<ul style="list-style-type: none"> <li>■ Acute or chronic abdominal pain due to pancreatitis or pancreatic, gastric, esophageal, or biliary malignancies.</li> <li>■ Pain related to mesenteric vascular occlusive disease</li> <li>■ Acute pain after liver embolization</li> </ul>	<ul style="list-style-type: none"> <li>■ Orthostatic hypotension</li> <li>■ Diarrhea</li> <li>■ Backache</li> <li>■ Uncommon: retroperitoneal hemorrhage, paraplegia, transient cord damage, aortic dissection, sexual dysfunction related to sympathetic chain neurolysis, and fistula formation</li> </ul>	<ul style="list-style-type: none"> <li>■ Celiac plexus block can be done with local anesthetic and glucocorticoids, or a neurolytic agent such as alcohol or phenol, for prolonged relief (3 months or more).</li> <li>■ In patients with cancer pain, there is an increased tendency to proceed with neurolysis from the start, given the high efficacy of the blocks and to avoid repeated procedures and delayed pain relief.</li> </ul>

### HOW TO PERFORM

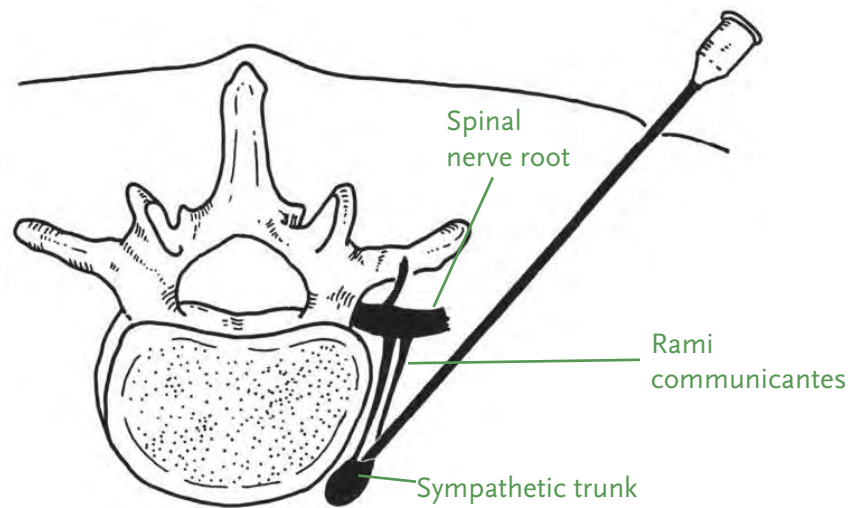
- A 5- or 7-inch spinal needle is placed along the celiac plexus (at the level of the L1 vertebra) under fluoroscopic guidance. The celiac plexus is at the level of the L1 vertebra and can be approached in several manners, but transcrural or retrocrural approaches are used most often. A small amount of contrast is commonly used to confirm needle positioning and lack of vascular uptake.
- After correct needle placement is confirmed, a local anesthetic (bupivacaine and/or lidocaine) is injected with or without a glucocorticoid (methylprednisolone). If the initial test dose relieves the pain, neurolysis can be performed using 50% to 95% alcohol (10–20 mL on each side) or 5% to 10% phenol (10–15 mL on each side).

#### References:

1. Eisenberg E et al. Neurolytic celiac plexus block for treatment of cancer pain: A meta-analysis. *Anesth Analg* 1995; 80:290.
2. Jain P et al. Celiac plexus blockade and neurolysis: An overview. *Indian J Anaesth* 2006; 509:169.

# SYMPATHETIC NERVE BLOCKS

## Lumbar Sympathetic Block



Cross section of lumbar sympathetic block

INDICATIONS	POTENTIAL COMPLICATIONS	CLINICAL PEARLS	HOW TO PERFORM
<ul style="list-style-type: none"> <li>■ Complex regional pain syndrome (CRPS) and other sympathetically mediated neuropathic pain phenomena affecting the lower limb</li> <li>■ Early postherpetic neuralgia</li> <li>■ Early phantom limb pain</li> <li>■ Vascular insufficiency affecting the lower extremities</li> </ul>	<ul style="list-style-type: none"> <li>■ Postprocedural back pain</li> <li>■ Bleeding</li> <li>■ Infection</li> <li>■ Intravascular injection of medication</li> <li>■ Local anesthetic systemic toxicity, if iatrogenic overdose combined with intravascular injection</li> <li>■ Disk puncture and possible diskitis</li> <li>■ Genitofemoral neuritis</li> <li>■ Renal or ureter puncture</li> <li>■ Transient neural blockade from posterior spread of local anesthetic to epidural or subarachnoid spaces (rare)</li> <li>■ Retrograde ejaculation if bilateral sympathectomy is performed</li> </ul>	<ul style="list-style-type: none"> <li>■ A one-needle technique (approaching from one side only) at L2 or L3 is usually used. However, if contrast spread to both sides is not observed, a 2-needle approach (repeating the procedure on the contralateral side) is used at L2 and L4 concurrently.</li> <li>■ If block provides good but short-term relief, neurolysis with phenol or alcohol can be used as a next step.</li> <li>■ In CRPS, lumbar sympathetic block should be combined with alternative treatments, including extensive physical therapy (as desensitization therapy) to provide best results.</li> </ul>	<ul style="list-style-type: none"> <li>■ A 5- to 7-inch bent-tip spinal needle is placed along the sympathetic chain at the level of the L2 or L3 vertebral body, under fluoroscopic guidance. A small amount of contrast is commonly used to confirm needle positioning.</li> <li>■ A skin-temperature probe is usually placed distally on the affected side; an increase in skin temperature of at least 2°C is used to confirm good blockade.</li> <li>■ Intravenous access is needed in case of an adverse event and for moderate sedation if needed.</li> </ul>

**References:**

1. Straube S et al. Cervico-thoracic or lumbar sympathectomy for neuropathic pain and complex regional pain syndrome. *Cochrane Database Syst Rev* 2013; 9:CD002918.
2. Manjunath PS et al. Management of lower limb complex regional pain syndrome type 1: An evaluation of percutaneous radiofrequency thermal lumbar sympathectomy versus phenol lumbar sympathetic neurolysis — a pilot study. *Anesth Analg* 2008; 106:647.

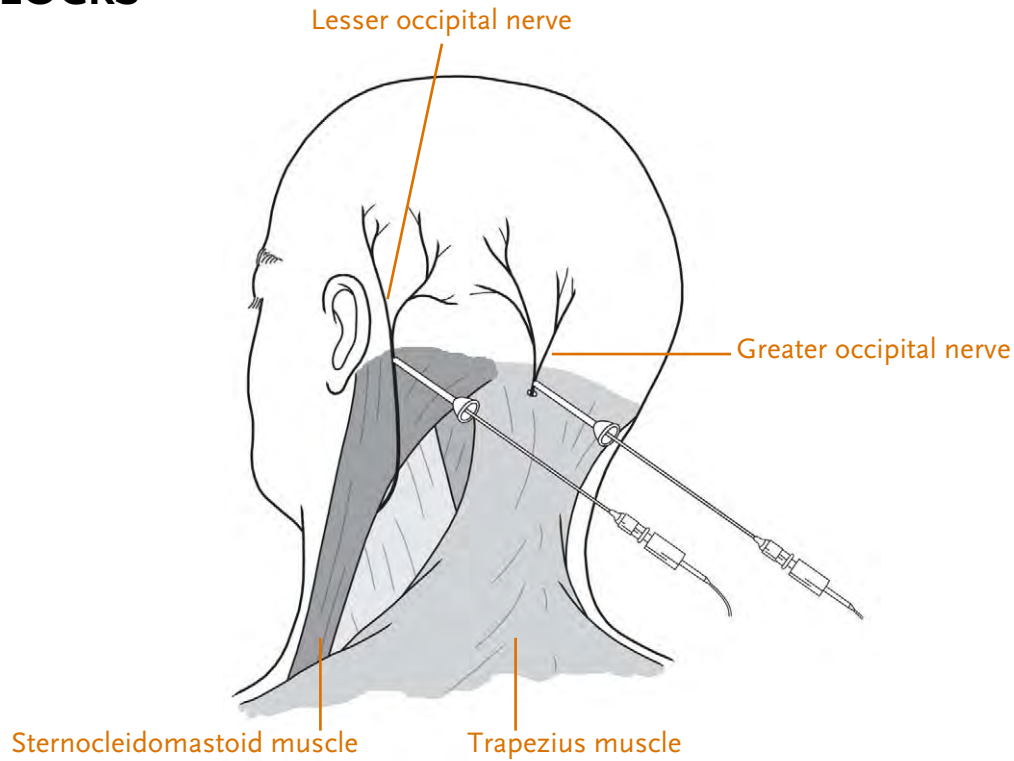
# HEAD AND NECK NERVE BLOCKS



**Nerve blocks of the head and neck** can be used for regional anesthesia and postoperative pain control, as well as for diagnostic and therapeutic purposes in managing conditions that cause chronic headaches. In the algorithm for treating chronic pain, the blocks are indicated when pharmacologic therapy is partially effective or ineffective in alleviating the patient's pain. Detailed knowledge of the relevant anatomy and of the use of fluoroscopy and ultrasound improves efficacy and minimizes complications.

# HEAD AND NECK NERVE BLOCKS

## Occipital Nerve Block



Location of greater and lesser occipital nerves

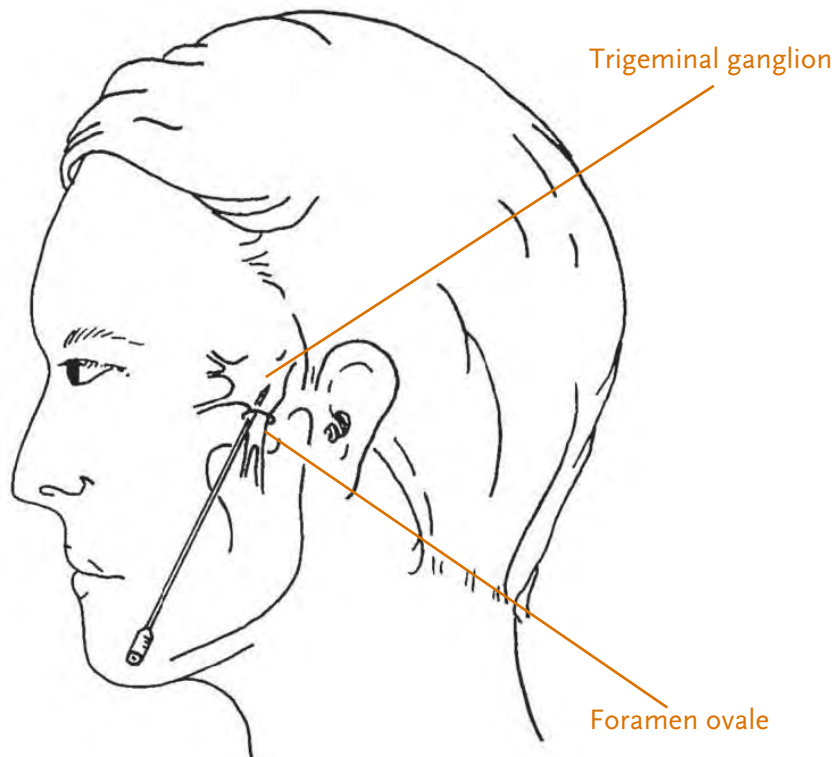
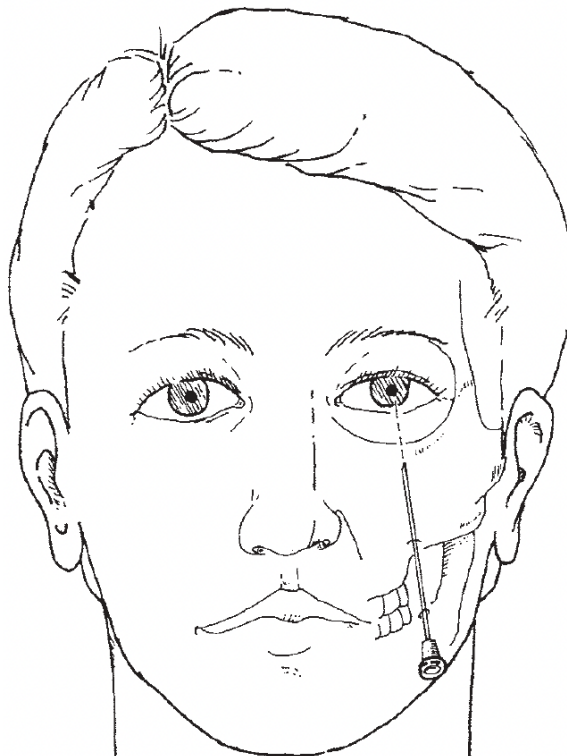
INDICATIONS	POTENTIAL COMPLICATIONS	CLINICAL PEARLS	HOW TO PERFORM
<ul style="list-style-type: none"> <li>■ Occipital neuralgia</li> <li>■ Cluster headache</li> <li>■ Cervicogenic headache</li> <li>■ Migraine</li> <li>■ As an adjuvant to medication-overuse headache</li> </ul>	<ul style="list-style-type: none"> <li>■ Infection</li> <li>■ Vasovagal reaction or syncope</li> <li>■ Small area of alopecia with cutaneous atrophy at glucocorticoid injection sites</li> <li>■ Puncture of occipital artery resulting in hematoma</li> <li>■ Peripheral facial nerve palsy</li> </ul>	<ul style="list-style-type: none"> <li>■ In patients with occipital neuralgia and clear but short-lasting response to greater occipital nerve blocks (ONBs), longer-term relief options include botulinum toxin injection, occipital nerve subcutaneous neurostimulation, and occipital nerve radiofrequency ablation.</li> <li>■ Response to ONB in patients with chronic migraine and chronic cluster headache does not reliably predict occipital nerve stimulator response.</li> </ul>	<ul style="list-style-type: none"> <li>■ A small needle is placed along the greater occipital nerve while the patient is seated.</li> <li>■ No imaging is typically required. However, given tremendous anatomic variability of the greater occipital nerve, ultrasound or electric nerve stimulation may be utilized.</li> <li>■ The lesser occipital nerve (located around two-thirds of the way between the occipital protuberance and the mastoid process) may also be blocked.</li> </ul>

**References:**

1. Voigt CL and Murphy MO. Occipital nerve blocks in the treatment of headaches: Safety and efficacy. *J Emerg Med* 2015; 48:115.
2. Blumenfeld A et al. Expert consensus recommendations for the performance of peripheral nerve blocks for headaches — A narrative review. *Headache* 2013; 53:437.

## Trigeminal Nerve Block

# 10



Needle direction for trigeminal nerve block

*continued on next page ↓*



## Trigeminal Nerve Block

# 10

INDICATIONS	POTENTIAL COMPLICATIONS	CLINICAL PEARLS	HOW TO PERFORM
<ul style="list-style-type: none"> <li>■ Trigeminal neuralgia</li> <li>■ Palliation of cancer pain in head and neck</li> <li>■ Acute herpes zoster</li> <li>■ Postherpetic neuralgia</li> <li>■ Acute facial pain emergencies</li> </ul>	<ul style="list-style-type: none"> <li>■ Dysesthesias</li> <li>■ Anesthesia dolorosa</li> <li>■ Weakness of the muscles of mastication</li> <li>■ Facial hematoma</li> <li>■ Secondary facial asymmetry</li> <li>■ Meningitis</li> <li>■ Intracranial hemorrhage with inadvertent intracranial needle placement</li> <li>■ Total spinal anesthesia</li> </ul>	<ul style="list-style-type: none"> <li>■ Interventional pain procedures are usually considered only after failure of more-conservative interventions. As trigeminal nerve block is a particularly complex procedure with a higher risk for complications, reserving its use to cases where conservative interventions have failed to adequately control pain is particularly important.</li> <li>■ Trigeminal nerve block may be a useful tool for treating acute exacerbations of trigeminal neuralgia, rather than chronic management. For longer-term relief, radiofrequency ablation or neuromodulation may be a viable option.</li> </ul>	<ul style="list-style-type: none"> <li>■ A 2.5- to 3.5-inch spinal needle is placed near the trigeminal nerve under fluoroscopic guidance. A small amount of contrast is commonly used to confirm needle positioning.</li> <li>■ The injectate is a combination of a local anesthetic (lidocaine or bupivacaine) and a glucocorticoid (typically dexamethasone). If chemical neurolysis is considered, a neurolytic agent such as phenol, alcohol, or glycerol may be used.</li> </ul>

**References:**

1. Raj P et al., editors. *Interventional pain management: Image-guided procedures*, 2nd ed. Philadelphia: Saunders Elsevier; 2008.
2. Waldman S, editor. *Atlas of interventional pain management*, 4th ed. Philadelphia: Saunders Elsevier; 2015.

# PERIPHERAL NERVE BLOCKS

11  
Ilioinguinal

**Peripheral nerve blocks** are commonly used for perioperative and chronic pain management. Almost any peripheral nerve can be blocked, if needed, guided by ultrasound or fluoroscopy. Peripheral nerve blocks are used for both diagnostic and therapeutic purposes.

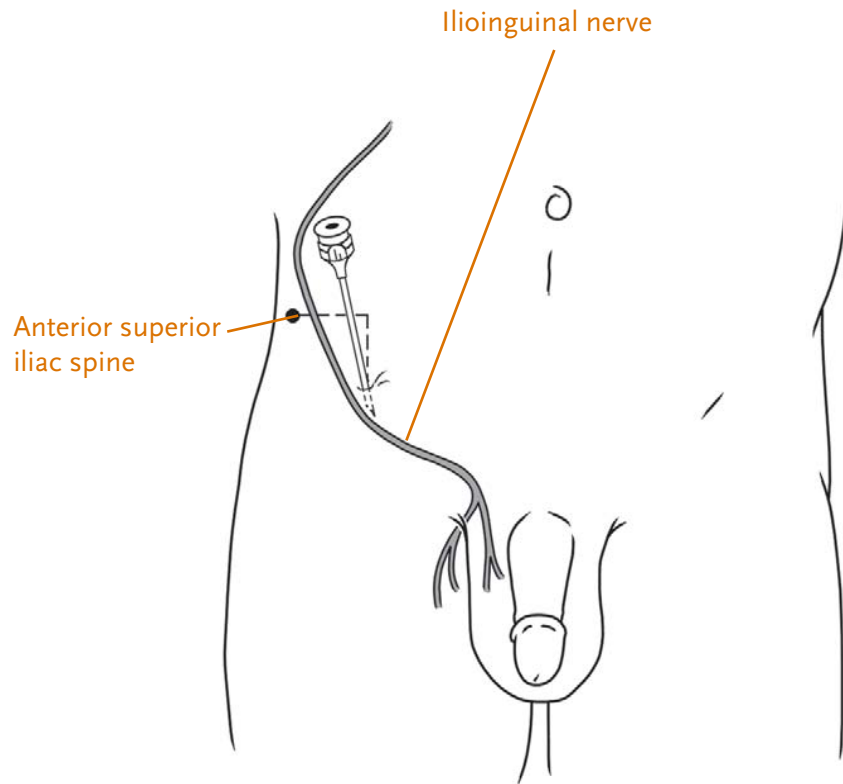
12  
Lateral Femoral

13  
Pudendal

14  
Genicular Nerve  
Block

# PERIPHERAL NERVE BLOCKS

## Ilioinguinal Nerve Block



Location of needle entry for ilioinguinal nerve block

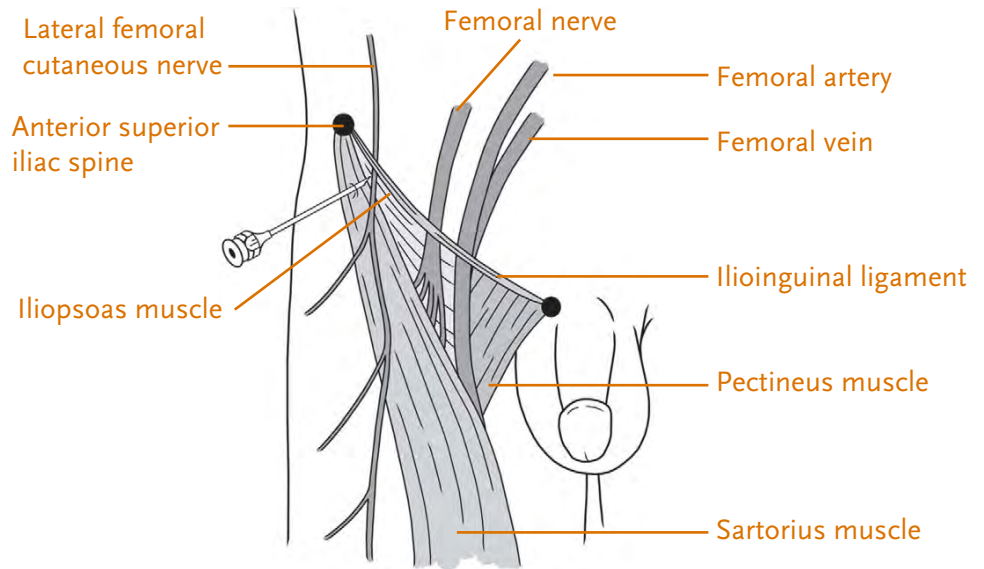
INDICATIONS	POTENTIAL COMPLICATIONS	CLINICAL PEARLS	HOW TO PERFORM
<ul style="list-style-type: none"> <li>■ Pain in the inguinal region, most commonly postoperative neuralgia after herniorrhaphy or lower abdominal surgery in the region of the ilioinguinal nerve</li> </ul>	<ul style="list-style-type: none"> <li>■ Inadvertent bowel perforation</li> <li>■ Infection</li> <li>■ Bleeding or hematoma</li> <li>■ Postprocedural pain and paresthesia</li> <li>■ Nerve injury</li> </ul>	<ul style="list-style-type: none"> <li>■ The procedure is typically done under ultrasound guidance, but it may be performed by anatomical landmarks. In this case, a large volume of injectate is recommended to ensure proper blockade.</li> <li>■ Nerve block offers a prognosis for the effectiveness of neuroablative or neurolytic therapies for longer-term relief.</li> </ul>	<ul style="list-style-type: none"> <li>■ A small needle is placed along the ilioinguinal nerve under ultrasound guidance.</li> <li>■ Once the needle is in position, 5 to 10 mL of the injectate is administered along the nerve.</li> </ul>

**Reference:**

Brown DL. Ilioinguinal nerve block. In: Atlas of regional anesthesia, 4th ed. Philadelphia: Saunders; 2010.

# PERIPHERAL NERVE BLOCKS

## Lateral Femoral Cutaneous Nerve Block



Location of needle entry for lateral femoral cutaneous nerve block

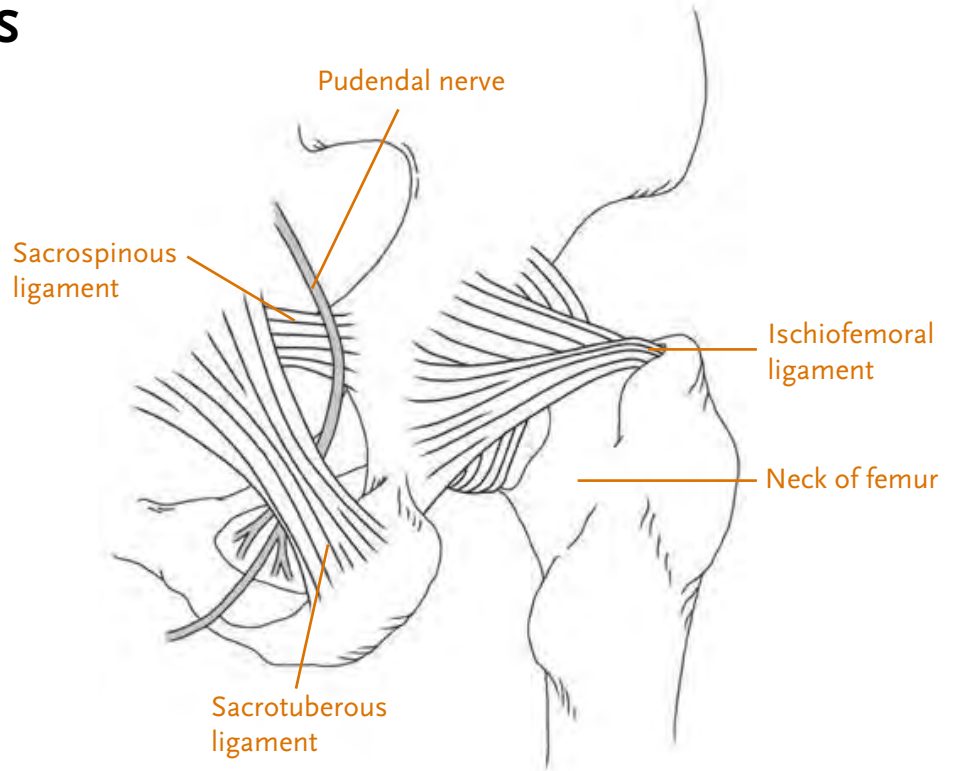
INDICATIONS	POTENTIAL COMPLICATIONS	CLINICAL PEARLS	HOW TO PERFORM
<ul style="list-style-type: none"> <li>■ Useful in diagnosing and treating the entrapment neuropathy of the lateral femoral cutaneous nerve (LFCN), known as meralgia paresthetica</li> <li>■ Can be used for surgical anesthesia and/or postoperative pain control for procedures on the anterolateral thigh, such as skin graft harvesting</li> </ul>	<ul style="list-style-type: none"> <li>■ Bleeding or ecchymosis</li> <li>■ Concomitant femoral nerve blockade</li> <li>■ Trauma to the LFCN or femoral nerve</li> </ul>	<ul style="list-style-type: none"> <li>■ The procedure is typically done under ultrasound guidance. Undergoing the procedure by only anatomic landmark is not recommended given the highly variable anatomic course of the LFCN.</li> <li>■ Given the superior efficacy of the ultrasound-guided LFCN block, if a patient with symptoms consistent with meralgia paresthetica does not respond to blockade of the nerve, lesions in the lumbar plexus or L2–3 radiculopathy should be considered.</li> </ul>	<ul style="list-style-type: none"> <li>■ With the patient supine, a small needle is placed along the LFCN using either anatomical landmarks or (highly recommended) under ultrasound guidance.</li> <li>■ Once correct positioning of the needle is confirmed, 5 to 10 mL of the injectate is administered.</li> </ul>

**References:**

1. Hurdle M et al. Ultrasound-guided blockade of the lateral femoral cutaneous nerve: Technical description and review of 10 cases. Arch Phys Med Rehabil 2007; 88:1362.
2. Tagliafico A et al. Ultrasound-guided treatment of meralgia paresthetica (lateral femoral cutaneous neuropathy): Technical description and results of treatment in 20 consecutive patients. J Ultrasound Med 2011; 30:1341.

## Pudendal Nerve Block

# 13



Landmarks to identify the course of the pudendal nerve

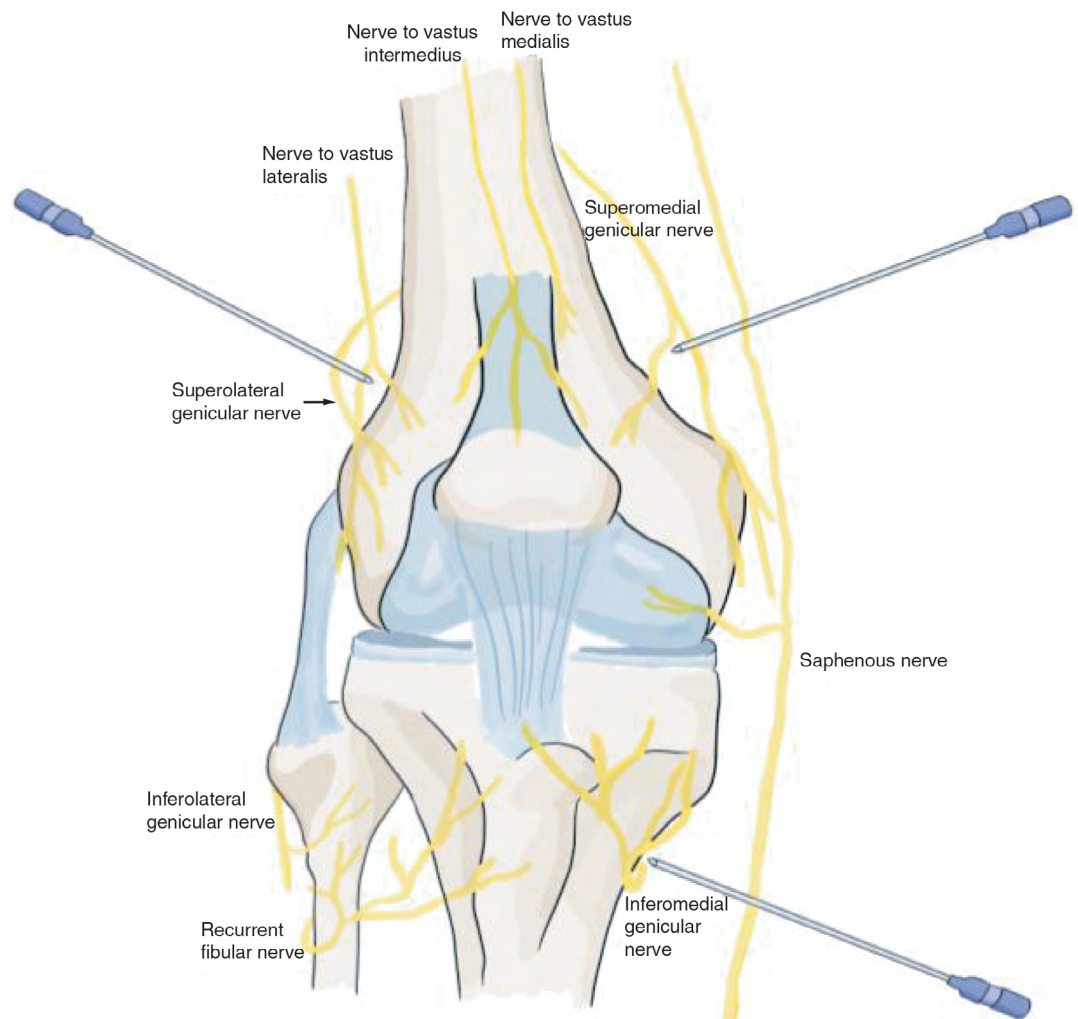
INDICATIONS	POTENTIAL COMPLICATIONS	CLINICAL PEARLS	HOW TO PERFORM
<p><b>Pudendal neuralgia:</b></p> <ul style="list-style-type: none"> <li>■ Diagnostically (a positive response is part of the diagnostic Nantes criteria)</li> <li>■ Therapeutically, to provide analgesia</li> </ul>	<ul style="list-style-type: none"> <li>■ Intravascular injection of medication</li> <li>■ Sciatic nerve injury</li> <li>■ Hematoma</li> <li>■ Perforated rectum (infection, fistula)</li> </ul>	<p><b>The five essential diagnostic criteria for pudendal neuralgia by pudendal nerve entrapment (Nantes criteria):</b></p> <ol style="list-style-type: none"> <li>1. Pain in the anatomical territory of the pudendal nerve</li> <li>2. Worsened by sitting</li> <li>3. The pain does not awaken the patient at night</li> <li>4. No objective sensory loss on clinical examination</li> <li>5. Positive anesthetic pudendal nerve block (pain relief with this procedure)</li> </ol>	<ul style="list-style-type: none"> <li>■ Pudendal nerve block can be attained by a transvaginal or a transrectal approach (landmark technique), a fluoroscopy- or ultrasound-guided transgluteal approach, or as a fluoroscopy-guided transsacral S2–S4 block.</li> <li>■ With fluoroscopy guidance, a small amount of contrast is commonly used to confirm needle positioning; then 3 to 5 mL of the injectate is administered slowly along the nerve.</li> </ul>

**References:**

1. Bellingham GA et al. Randomized controlled trial comparing pudendal nerve block under ultrasound and fluoroscopic guidance. *Reg Anesth Pain Med* 2012; 37:262.
2. Peng PWH. Pudendal nerve. In: Peng PWH, editor. *Ultrasound for pain medicine intervention: A practical guide, volume 2: Pelvic pain*. Electronic book; 2014.

## Genicular Nerve Block

# 14



*continued on next page ↓*

## Genicular Nerve Block

# 14

INDICATIONS	POTENTIAL COMPLICATIONS	CLINICAL PEARLS	HOW TO PERFORM
<p><b>Genicular nerve block can be an option to treat chronic knee pain caused by:</b></p> <ul style="list-style-type: none"> <li>■ Osteoarthritis of the knee</li> <li>■ Persistent knee pain after surgery, such as arthroscopy or partial or total knee replacement</li> </ul> <p>Nerve block is typically considered when conservative measures (e.g., physical therapy, acetaminophen, or nonsteroidal antiinflammatory drugs) or intra-articular treatments (e.g., glucocorticoid injections or viscosupplementation) are either ineffective or contraindicated.</p> <p>Genicular nerve block is also useful in patients with chronic pain from knee osteoarthritis who are not candidates for knee replacement (for example, because of other medical comorbidities)</p>	<ul style="list-style-type: none"> <li>■ Infection</li> <li>■ Bleeding or hematoma</li> <li>■ Postprocedural pain and paresthesia</li> <li>■ Intravascular injection of the medication</li> </ul>	<p><b>The knee is innervated by several genicular nerves, but the three primary nerves that run along the bones provide targets for fluoroscopy and ultrasound:</b></p> <ul style="list-style-type: none"> <li>■ Superior lateral (SL) nerve (along the femur)</li> <li>■ Superior medial (SM) nerve (along the femur)</li> <li>■ Inferior medial (IM) nerve (along the tibia)</li> </ul> <p>The inferolateral genicular nerve is spared, especially if denervation is planned, because of its proximity to the common peroneal nerve (CPN) to avoid unintended CPN block and foot drop.</p> <p>Genicular nerve blocks can be diagnostic or therapeutic. A diagnostic block helps to determine if the knee is the source of pain. A single block, or two blocks as part of a double comparative set of diagnostic blocks, might help determine whether radiofrequency ablation of the genicular nerves should be performed.</p>	<ul style="list-style-type: none"> <li>■ The procedure can be done under fluoroscopic guidance (most common) or ultrasound guidance. The genicular nerves are small and cannot be visualized by ultrasound, but landmarks can be used.</li> <li>■ Under fluoroscopic guidance, the target areas along the femur and tibia are identified in AP position; a lateral view is then used before needle insertion.</li> <li>■ Usually, the target areas are superficial enough that a 1.5-inch hypodermic needle can be used. If that is not long enough, then 1% lidocaine can be injected while the needle is pulled out, and a longer 2.5- or 3.5-inch Quincke needle can be reinserted to reach the target nerves.</li> <li>■ For a diagnostic block, only a long-acting anesthetic, such as bupivacaine, can be used. For therapeutic blocks, a glucocorticoid can be added. Only 1 mL of injectate is needed at each target area.</li> </ul>

**References:**

1. Waldman SD: Genicular nerve block. In *Atlas of Pain Management Injection Techniques*. Fourth Edition. St. Louis, Missouri, 2017, Saunders, 173, 785-793.
2. Choi WJ et al. Radiofrequency treatment relieves chronic knee osteoarthritis pain: a double-blind randomized controlled trial. *Pain* 2011 Mar; 152:481.

# DRY NEEDLING AND TRIGGER POINT INJECTIONS

## Dry Needling and Trigger Point Injections

**Trigger points** refer to taut bands of skeletal muscle that can cause point tenderness or referred pain and, sometimes, twitching of the muscle when it is compressed. Risk factors for development of myofascial pain include acute trauma or repetitive microtrauma, overextension of a muscle, poor posture, or sports or occupational injuries. Insertion of a needle (dry needling) or injection of local anesthetic (trigger point injections) into the trigger points can be used to help relieve this pain.

INDICATIONS	POTENTIAL COMPLICATIONS	CLINICAL PEARLS
<ul style="list-style-type: none"><li>■ Pain secondary to the presence of myofascial trigger points</li></ul>	<ul style="list-style-type: none"><li>■ Increased pain</li><li>■ Nerve damage</li><li>■ Infection</li><li>■ Bleeding</li><li>■ Vasovagal syncope</li><li>■ Pneumothorax</li></ul>	<ul style="list-style-type: none"><li>■ Myofascial trigger points are identified by palpation causing localized pain, referred pain, or a local twitch response. These trigger points are often seen or palpated as “bands” or “knots” of muscle.</li><li>■ Myofascial pain syndrome is diagnosed clinically through history and physical examination, though new techniques such as pressure algometry and ultrasound can be utilized.</li><li>■ Anticoagulants do not need to be stopped prior to trigger point injections, although less “fanning” is recommended to avoid significant hematoma formation.</li></ul>

### HOW TO PERFORM

- An appropriately sized needle is repeatedly inserted into the myofascial trigger point in a fan-like manner (“fanning”) to cause muscle-fiber relaxation and lengthening, and disrupt the connective tissue.
- Larger needles are used for larger muscle groups such as the lumbar paraspinal muscles. Shorter needles (1/2- to 5/8-inch needles) are used for smaller muscles or if there is increased risk for pneumothorax (e.g., in the cervical or thoracic paraspinal region).
- Dry needling is the insertion of the needle without any injection, whereas trigger point injections involve injection of saline or a local anesthetic (avoiding long-acting anesthetics such as bupivacaine, as they can be myotoxic). Glucocorticoids are generally also best avoided given concerns about systemic side effects and myotoxicity.

#### References:

1. Alvarez DJ and Rockwell PG. Trigger points: Diagnosis and management. *Am Fam Physician* 2002; 65:653.
2. Borg-Stein J and Iaccarino MA. Myofascial pain syndrome treatments. *Phys Med Rehabil Clin N Am*. 2014; 25:357.



## Intrathecal Drug Delivery

# 16

**Minimally invasive surgical procedures** represent an essential, evolving approach to treating chronic pain. Currently, there are two broad categories of these procedures: intrathecal drug delivery and neuromodulation.

**Intrathecal Drug Delivery.** These procedures directly deliver medications into the cerebral spinal fluid, thereby having potent analgesic effects while minimizing systemic adverse effects from oral administration of medication. The only FDA-approved medications for intrathecal delivery are morphine, ziconotide, and baclofen. In practice, however, other agents are also used; these include hydromorphone, fentanyl, clonidine, and a local anesthetic (such as bupivacaine). When monotherapy fails to provide adequate analgesia, combinations of several classes of medications are used instead, most commonly in the form of mixed opioid and local anesthetic solutions.

## Neuromodulation (Spinal Cord Stimulation)

# 17

**Neuromodulation.** The mechanism of action of neuromodulation is only partially understood. One proposed mechanism is based on the “gate-control” theory of pain: The neuromodulation device provides an electric signal, which serves as a nonpainful stimulus, thereby modulating pain transmission in the central nervous system. This “closing the gate” to the transmission of painful sensations leads to analgesia. Spinal cord stimulation and peripheral nerve stimulation are two types of neuromodulation.

## Neuromodulation (Peripheral Nerve Stimulation)

# 18

## Intrathecal Drug Delivery

INDICATIONS	POTENTIAL COMPLICATIONS	CLINICAL PEARLS
<ul style="list-style-type: none"> <li>■ Malignant pain</li> <li>■ Nonmalignant pain</li> <li>■ Spasticity</li> </ul> <p>Patients must have persistent, debilitating pain or spasticity that is not responsive to more-conservative treatments.</p>	<ul style="list-style-type: none"> <li>■ Intraoperative injury to the nerve roots or spinal cord</li> <li>■ Bleeding and hematoma formation</li> <li>■ Infection: Deeper infection may require explantation of the entire system.</li> <li>■ Catheter-related malfunctions (e.g., kinks)</li> <li>■ Intrathecal granuloma (rare but serious)</li> </ul>	<ul style="list-style-type: none"> <li>■ Intrathecal therapy, especially in advanced cancer and in patients with upper neuron spasticity, has been shown to provide improved analgesia with fewer side effects, compared with oral therapy.</li> </ul>

### HOW TO PERFORM

Patients for whom intrathecal drug delivery is being considered must first undergo a trial of neuraxially administered medication (local anesthetic ± opioid or baclofen) to determine whether therapy will provide an adequate clinical effect. Although epidural and intrathecal single-shot trials can be done, the preferred method involves placement of an intrathecal catheter to best mirror potential implant conditions. Hospital admission is generally recommended to monitor for adverse effects while adjusting the continuous epidural infusion to achieve efficacy. A successful trial is usually defined as an at least 50% improvement in pain and/or functional status.

If there is benefit, the patient is taken to the operating room, where the procedure is done under fluoroscopic guidance. Intravenous access is required. Depending on physician preference and patient comorbidities, the procedure can be performed with local anesthesia and sedation or general anesthesia. Prophylactic antibiotics (e.g., cefazolin) also are required before surgery.

A catheter is first placed into the epidural space under fluoroscopic guidance. The location is chosen to correspond to the dermatome that corresponds to the center of the patient's pain. Up to 6 spinal segments are usually covered well by an intrathecal opioid infusion, but as many as 10 segments may be reached.

The catheter is tunneled under the skin of the abdominal wall and connected to the infusion pump. The pump is typically placed in the anterior abdominal wall for easy access. Patients recover quickly after surgery and usually return to their normal activities within one month.

The patient needs follow-up every 1 to 3 months for pump refills, whereby leftover medicine is extracted by a needle percutaneously from the reservoir, and replaced with new medication(s). The pump reservoir needs to be exchanged every 7 to 10 years via a minimal surgical procedure.

#### References:

1. Deer TR et al. Comprehensive consensus guidelines on intrathecal drug delivery systems in the treatment of pain caused by cancer pain. *Pain Physician* 2011; 214:E283.
2. Deer TR et al. Consensus guidelines for the selection and implantation of patients with noncancer pain for intrathecal drug delivery. *Pain Physician* 2010; 13:E175.

## Neuromodulation (Spinal Cord Stimulation)

INDICATIONS	POTENTIAL COMPLICATIONS	CLINICAL PEARLS
<p>Spinal cord stimulation (SCS) is a treatment option for severe neuropathic pain that is not responsive to more-conservative treatments.</p> <p><b>Common indications:</b></p> <ul style="list-style-type: none"> <li>■ Failed back surgical syndrome</li> <li>■ Complex regional pain syndrome (CRPS) types 1 and 2</li> <li>■ Painful radiculopathies</li> <li>■ Painful diabetic neuropathy</li> </ul> <p><b>Other indications:</b></p> <ul style="list-style-type: none"> <li>■ Painful peripheral vascular disease</li> <li>■ Postherpetic neuralgia</li> <li>■ Axial low-back pain</li> </ul>	<ul style="list-style-type: none"> <li>■ Bleeding and hematoma formation (around pocket area or epidural space)</li> <li>■ Infection (deeper infections may require explantation of the entire system)</li> <li>■ Postdural headache</li> <li>■ Spinal cord or nerve root damage</li> <li>■ Lead migration and lead fracture, evidenced by loss of analgesia</li> </ul>	<ul style="list-style-type: none"> <li>■ Neuromodulation has shown substantial advancement in the past several years, with significant improvement in the device itself and inclusion of more indications.</li> <li>■ However, it remains a technically challenging surgical pain-management procedure that merits extensive training and understanding of neuroanatomy, surgical technique, and perioperative patient care.</li> <li>■ When performed by experienced providers, it offers a viable alternative to patients who have persistent pain despite maximizing other treatments, with fewer overall side effects.</li> </ul>

### HOW TO PERFORM

Patients in whom spinal cord stimulation is being considered must first undergo a 7- to 10-day trial. One or two leads are inserted percutaneously under fluoroscopic guidance and advanced in the epidural space to the desired locations. For low-back or lower-extremity pain, a common epidural entry site is L1–L2 with the leads located at the top of T8 and mid-T9 vertebrae. For upper-extremity pain, a common epidural entry site is T1–T2 with an electrode tip at C2. During the trial, the leads are attached to an external generator, and the patient’s pain level, function, and quality of life are assessed. A successful trial is defined as showing at least a 50% improvement in pain or functional status. At the end of the trial, the leads are removed and discarded.

If there is benefit, the patient returns for implantation of the permanent device. This procedure is done in the operating room under monitored anesthesia care and fluoroscopic guidance. Prophylactic antibiotics (cefazolin) are required before the trial and permanent surgical implant.

A lead is placed in a similar manner to the placement during the trial, and it is tunneled subcutaneously to the implantable pulse generator. The pulse generator is usually placed in the lower abdominal wall area, either on the left or right side depending on patient preference. Generally, the device is not turned on until the 1-week follow-up appointment (when surgical pain subsides).

Patients have quick surgical recovery. They usually return to light work within 5 to 7 days and can perform graded strenuous activities after one month. The generator is charged externally every 1 to 3 days, and it needs to be exchanged every 7 to 10 years via a minimal surgical procedure.

**Reference:**

Kumar K et al. The effects of spinal cord stimulation in neuropathic pain are sustained: A 24-month follow-up of the prospective randomized controlled multicenter trial of the effectiveness of spinal cord stimulation. *Neurosurgery* 2008; 63:762.

## Neuromodulation (Peripheral Nerve Stimulation)

INDICATIONS	POTENTIAL COMPLICATIONS	CLINICAL PEARLS
<p>Peripheral nerve stimulation is indicated in most conditions that result in severe neuropathic pain in a dermatomal distribution of a particular nerve that does not respond to more-conservative treatments. Examples of such conditions include:</p> <ul style="list-style-type: none"> <li>■ Median, ulnar, and radial neuropathy</li> <li>■ Occipital neuralgia</li> <li>■ Cluneal nerve pain</li> <li>■ Pudendal neuralgia</li> <li>■ Femoral, sciatic, and obturator neuropathy</li> <li>■ Brachial and lumbar plexus neuropathy</li> <li>■ Meralgia paresthetica</li> <li>■ Lumbar and cervical radiculitis</li> <li>■ Intercostal neuralgia</li> </ul>	<ul style="list-style-type: none"> <li>■ Pain during the procedure</li> <li>■ Infection (may require antibiotic therapy, removal of the lead, or both)</li> <li>■ Hematoma formation</li> <li>■ Lead migration (most common complication), fracture, or misplacement</li> <li>■ Stimulation intolerance</li> <li>■ Nerve damage</li> </ul>	<ul style="list-style-type: none"> <li>■ Peripheral stimulators can be placed for a short period of time (60 days) with expected long-term benefit (can be up to one year or more), or they can be placed permanently.</li> <li>■ Peripheral nerve stimulators can successfully treat postoperative and acute pain, with minimal need for opioid medications.</li> <li>■ Peripheral nerve stimulation can be a viable option for patients with chronic neuropathic pain who have contraindications to placement of spinal cord stimulators.</li> </ul>

### HOW TO PERFORM

Peripheral nerve stimulation is typically performed under local anesthesia. Using ultrasound guidance, the clinician injects a local anesthetic along the track of proposed needle insertion. A monopolar needle is then inserted, again under ultrasound guidance, up to 0.5 cm to 1 cm from the target nerve. An electrical stimulator is attached to the needle to deliver a test stimulation. The stimulator needle is readjusted until uncomfortable sensations and muscle contractions are no longer present.

Once the stimulator needle is confirmed to be in the correct position, it gets withdrawn, and the introducer needle preloaded with the stimulator lead is placed in the same location. The needle is then removed over the stimulator lead, and the lead can then be attached to the generator, which is generally placed externally.

Appropriate placement results in comfortable sensations in the desired region without muscle contractions when electrical stimulation is on.

#### Reference:

Chow RM et al. Peripheral nerve stimulation for pain management: a review. *Curr Pain Headache Rep* 2023 Sep; 27:321.

# COMMON INTERVENTIONAL PAIN PROCEDURES

*Last reviewed Oct 2023. Last modified Oct 2023.*

*The information included here is provided for educational purposes only. It is not intended as a sole source on the subject matter or as a substitute for the professional judgment of qualified healthcare professionals. Users are advised, whenever possible, to confirm the information through additional sources.*

**Figures:**

Raj PP et al. *Interventional pain management: Image-guided procedures*, 2nd ed. Philadelphia: Saunders/Elsevier 2008.

Kong C et al. Genicular nerve block for emergency department patient: a successful management of subacute osteoarthritic knee pain. *Pain Manag* 2023 Jul; 13:373.

All figures republished with permission.



© 2023 Massachusetts Medical Society. All rights reserved.