

## PLASTIC BRONCHITIS

BY

R. SLEIGH JOHNSON AND E. G. SITA-LUMSDEN

*From Southend-on-Sea Hospital, Essex*

(RECEIVED FOR PUBLICATION MAY 18, 1960)

The specific feature of plastic bronchitis is the formation of obstructive bronchial plugs or casts of thick, tenacious mucus during an attack of bronchitis, when one or more lobes or even an entire lung may collapse. Casts are often expectorated, but they may be discovered only at bronchoscopy, or be found lying in the bronchial tree at necropsy. They consist largely of mucus, and may also contain fibrin, pus cells, and blood, as well as elements commonly found in asthmatic attacks such as eosinophil cells, Charcot-Leyden crystals, and Curshmann's spirals.

### CASE REPORTS

CASE 1.—A married woman, previously in good health, had her first respiratory illness, left lower lobe pneumonia, in 1937 at the age of 27, followed by another attack three years later. In 1941, her house was demolished by a land-mine, when she was heavily exposed to dust and sustained severe nervous shock. Shortly afterwards she developed attacks of cough, dyspnoea, and wheezing, relieved by adrenalin and antispasmodic inhalations. The attacks occurred every few weeks during the winter, often following a head cold; a small amount of yellow sputum was produced. Other precipitating factors were emotional upset, excitement, or exertion.

In April, 1951, she had an attack of sinusitis with wheezing, following the death of her mother. The first known incident of major pulmonary collapse occurred after using an adrenalin spray. She noticed a "peculiar noise" in the retrosternal region with increasing dyspnoea, cough with yellow sputum, malaise, and severe retrosternal pain spreading to the left chest and interscapular area. She was admitted to hospital with signs of complete collapse of the left lung, temperature of 100° F., leucocytosis of 11,200 per c.mm., and erythrocyte sedimentation rate of 33 mm. in one hour (Westergren). There were no specific bacteriological findings in the sputum. Postural drainage and breathing exercises proved ineffective, so she was bronchoscoped, and the left main bronchus was found to be blocked by viscid secretion, just distal to the carina. The secretion was successfully aspirated, revealing inflammatory changes in the mucosa of the left bronchus. Restoration of the airway was followed by rapid re-expansion at the left base and recovery.

She remained free from serious attacks until May, 1954, when after moving house a coryzal attack developed into acute bronchitis with asthma. She had severe, stabbing pain in the centre of the back and lower chest mainly on the left, induced by movement, coughing, or breathing. Dyspnoea was so severe that even speaking caused distress, and she became very ill with fever, sweating, cough, and creamy sputum. Admitted as an emergency, she had an immobile, silent left lung, and the heart and mediastinum were displaced to the left (Fig. 1).

As she did not improve, bronchoscopy was carried out: the left stem bronchus was completely obstructed by a plug of tough, inspissated mucus which appeared to be lightly adherent to the bronchial wall but proved too viscid to be dislodged by aspiration alone. It required to be broken up and removed in small pieces with forceps; when one large piece approximately 3 × 1 cm. was withdrawn, the air entry was immediately restored to the lower lobe bronchi with rapid

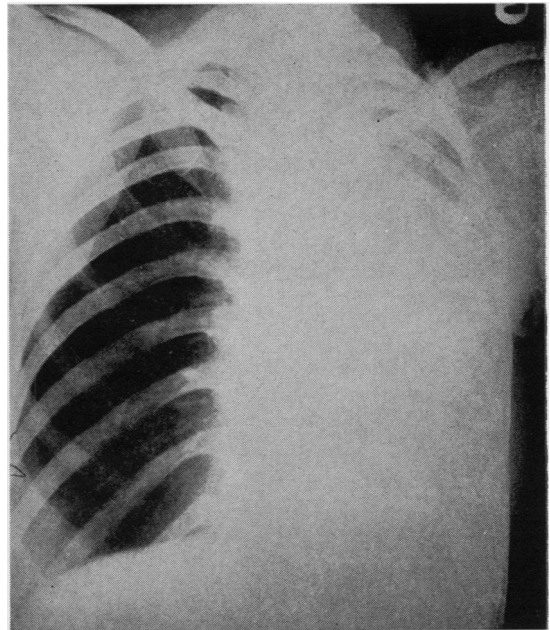


FIG. 1.—Radiograph of Case 1, showing total collapse of the left lung on her second admission.

relief of dyspnoea and general improvement. Later in the day a plug of dense, viscid mucus was expelled after a bout of coughing, resulting in further improvement in air entry. Treatment was continued with steam inhalation, antibiotics and antispasmodics, postural coughing, and breathing exercises. A small effusion developed at the left base, but six days after bronchoscopy the radiographic appearances were almost normal.

The pathological findings pointed to a combination of infection and allergy. A blood count on the day of admission showed a slight leucocytosis of 11,000 per c.mm. (84% polymorphonuclears and 1% eosinophils). Culture of sputum and bronchial suckings gave a heavy growth of pneumococci, but no acid-fast bacilli or fungi were found; clumps of hyperplastic bronchial epithelial cells were present, but no neoplastic cells were seen. The plug was of irregular shape and consisted of mucoid, eosinophilic acellular material in which were included numerous pyknotic cells and foci of leucocytes. Among the latter were needle-shaped and hexagonal Charcot-Leyden crystals, and outside the main mass were small acellular clumps of highly refractile, non-staining material resembling portions of Curshmann's spirals. The biopsy consisted of corrugated bronchial mucosa covered by regular epithelium, in places somewhat flattened, beneath which was a heavy infiltration by lymphocytes, plasma cells, and eosinophils, present also in the muscularis mucosae and mucous glands; there was no evidence of malignancy. Bronchograms made after discharge were normal.

The patient had a third episode of pulmonary collapse, once again in the spring, in March, 1957. Cough with a little sputum developed, attributed to inhalation of smoke from a train. Five days later she had severe pain in the centre of the back to the left of the midline, of constant intensity and radiating diffusely across the chest on breathing, accompanied by dyspnoea, malaise, and anxiety. On readmission she had faucial injection, tachycardia, and respiratory distress with signs again of left-sided pulmonary collapse, confirmed by radiographic examination. She had a leucocytosis of 21,000 per c.mm., 80% being polymorphonuclear cells with no excess of eosinophils, and the sedimentation rate was 21 mm. in one hour (Wintrobe). Sputum gave a growth of commensals only.

Bronchoscopy was performed shortly after admission, and the left stem bronchus found to be blocked by a greenish-grey plug of viscid glassy material to  $\frac{1}{2}$  in. below the carina, with much thin, bubbly mucus in each bronchial tree but no plug in the right bronchus. The mass was partly removed in fragments with difficulty by forceps and sucker, after which the almost complete remainder of the plug, about 6 $\frac{1}{2}$  cm. in length, was removed by forceps (Fig. 2). Part of a similar plug in the left upper lobe bronchus was also sucked out and air entry re-established to all main bronchi. Relief was rapid, and next day air entry throughout the left lung was much improved, though some mediastinal displacement

remained. There was still partial collapse of the anterior segment of the left upper lobe with a pleural reaction at the left base and fluffy shadowing had appeared in the lower two-thirds of the right lung. The temperature was raised to 100° F. but rapidly became normal, though after postural percussion and breathing exercises she coughed up copious mucoid sputum, which was slightly blood-stained at first. Penicillin and corticotrophin were given for four days, and five days after bronchoscopy the radiograph was normal and she was discharged (Fig. 3). Histological examination of the bronchial plug showed a mucoid matrix containing a large number of inflammatory cells, including many eosinophils. The material was acetic-acid-coagulable, and on hydrolysis, followed by chromatography, glucose, galactose, and ribose were identified, confirming that the main constituent was mucin.

A year later, after a cold, she developed wheezing with fever and bronchitis, more marked on the left side, with thick stringy mucus. She recovered rapidly after prompt treatment with antibiotics and prednisolone, which probably prevented a pulmonary collapse as in the three previous similar attacks. A film taken a week after recovery showed increased pulmonary basal markings only, and bronchography demonstrated slight dilatation of a single bronchus in the left posterior basal segment, not shown in the bronchograms of 1954.

Since March, 1958, the patient has not had any further major illness, but she has had occasional cough and mucoid sputum with mild wheezing at

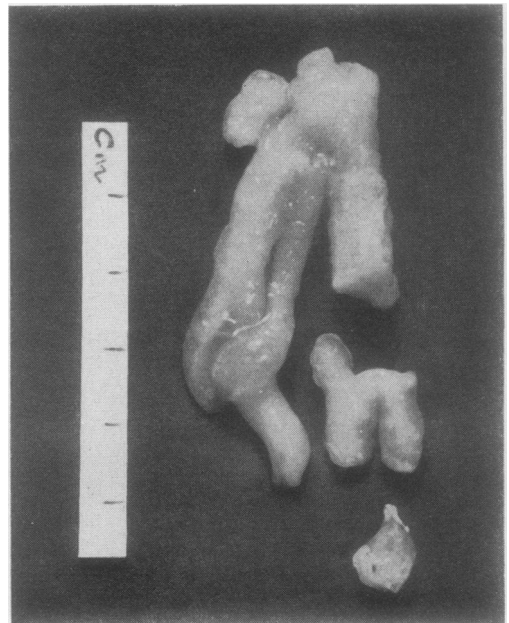


FIG. 2.—Fragments of the plug removed at bronchoscopy on the third admission of Case 1.

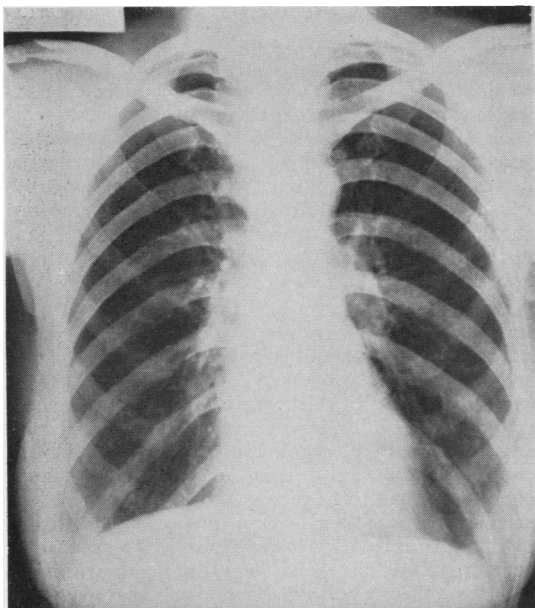


FIG. 3.—Radiograph of Case 1 on her third admission, showing complete re-expansion of the left lung after bronchoscopy.

times, readily controlled by ephedrine. The lungs have continued to show normal air entry on each side with a few scattered wheezes but no other signs. During one such attack in December, 1958, treated by tetracycline, she coughed up mucous plugs without chest pain. Skin tests in August, 1959, gave a strongly positive reaction to aspergillus antigen and mixed fungi (Bencard). There was no sputum at that time and her serum did not show any precipitating antibodies to *Aspergillus fumigatus*.

This patient had three major attacks of pulmonary collapse in seven years, and on each occasion was bronchoscoped with rapid relief.

CASE 2.—A retired nurse, aged 61, was admitted to hospital in March, 1948. Apart from heavy colds her health had been good until five months previously, when she had an influenzal illness with cough, high fever, and mucoid sputum. Similar febrile attacks had recurred, culminating in a sudden severe pain in the left chest and dyspnoea. There were signs of left basal pulmonary collapse with jugular engorgement and tracheal and mediastinal displacement. There was no bronchospasm and she was not febrile. Radiographs showed collapse of the left lower lobe and patchy collapse of the left upper lobe, the right lung field being clear. Leucocyte count was 5,100 per c.mm.; Friedländer's bacillus was grown from the mucopurulent sputum. Improvement was rapid on inhalations and alkaline expectorants, and radiographic examination six days later showed normal appearances.

In July, 1948, she was readmitted with similar symptoms, 12 days after breaking her right wrist.

Cough and dyspnoea developed on the night of the accident, followed by severe stabbing pain and tightness in the chest. She had a low fever and a continuous cough, producing a cupful daily of thick, tenacious, white sputum. Venous engorgement was seen in the neck, and there was diminished air entry, prolonged expiration, and a loud expiratory wheeze over the whole of the right chest as well as diffuse bronchitic signs. Cough and viscid sputum persisted until two weeks after admission, when increasingly severe dyspnoea and cyanosis developed with intractable cough and difficulty in expectoration. Chest radiographs then showed collapse of the pectoral segment of the right upper lobe. Her sputum was blood-stained and contained thick pieces of mucopus giving a predominant growth of *B. friedländeri*; no tubercle bacilli were found, and the leucocyte count was normal at 9,000 per c.mm. Five days later, after a severe bout of coughing in which no sputum could be raised spontaneously, she was greatly relieved when hard percussion resulted in the expectoration of a plug of tough mucus. Penicillin and streptomycin were given, together with an antihistamine and ephedrine, and the right lung re-expanded completely during the next four weeks.

In April, 1949, a further episode of pulmonary collapse led to her third hospital admission. She was able to bring up only a little sticky sputum with great effort and without relief of the tightness in the chest, and had a collapsed left upper lobe. Shortly after admission she coughed up a large plug of mucus with immediate relief of symptoms and rapid re-expansion of the left upper lobe. The plug was a cylindrical body of tough yellow mucus, 4 cm. long by 1.5 cm. diameter, containing small white flecks which proved to be colonies of haemolytic streptococci. Microscopy showed scanty pus cells, most of the cells being epithelial; no eosinophils or elastic fibres were seen but many crystals were present. A month later she had a sharp pain under the left scapula, and once again the left upper lobe and lingula had partially collapsed. The sedimentation rate had risen from normal to 72 mm. in one hour (Westergren). Spontaneous improvement occurred and she was discharged home in a few days.

The fifth incident occurred in January, 1950, when she was readmitted for a cough following a head cold with increasingly tenacious sputum and dyspnoea. She had severe bronchitis with transient signs of collapse at the left lung base. Pneumococci, staphylococci, and coliform bacilli were obtained from the sputum and she had a mild leucocytosis of 11,200 per c.mm. The chest infection responded quickly to streptomycin, breathing exercises, and postural percussion.

She was admitted for the sixth time two months later with increasing cough, dyspnoea, and sharp pain in the left lower chest. The left lower lobe was collapsed and the neck veins were engorged; scattered high-pitched wheezes were heard over the right lung. No specific organisms were found in the sputum and there was no leucocytosis. Bronchoscopy showed

the presence of thick secretions in the left lower lobe bronchus, which were removed by aspiration; biopsy from the right upper lobe showed no evidence of neoplasm. Vigorous physiotherapy was given as well as methylephedrine and penicillin, and she was discharged two weeks later with nearly complete expansion of the left lower lobe.

This patient illustrates the clinical features of relapsing plastic bronchitis with recurrent sudden atelectases occurring five times in the left lung and once in the right, with apparently complete recovery between attacks. She was bronchoscoped once only, for diagnosis and therapeutic aspiration.

CASE 3.—A married woman, aged 65, was admitted to hospital in October, 1942, with a provisional diagnosis of carcinoma of the left lung. She had had a winter cough for many years, but recently had had two attacks of sudden aching in the left shoulder and praecordium, with dry cough and breathlessness, each lasting a week. She had no sputum but was cyanosed, with congested neck veins, a temperature of 100° F., and signs of extensive collapse of the left lung, confirmed by a chest radiograph. At bronchoscopy a mass of jelly-like mucus was found in the left main bronchus; after this had been removed with difficulty by suction the bronchi appeared normal. Within two days she was afebrile, free of pain, and the left lung had completely re-expanded.

In September, 1943, she had a similar attack and was again found to have complete collapse of the left upper and lower lobes. Bronchoscopy showed that the left main bronchus was again obstructed by a mass of thick mucus, which was removed by suction and forceps; the mucosa appeared chronically inflamed but showed no evidence of neoplasm, and she recovered rapidly.

Similar events recurred three months later, necessitating her third admission. This time she had a slight fever and a leucocytosis of 15,000 c.mm., with collapse of the left lower lobe. A plug of thick black mucus was coughed up with great difficulty, and she then recovered uneventfully with a subsequent normal bronchoscopy and bronchogram.

She remained well for more than a year, but in February, 1945, had to be bronchoscoped for a recurrence of cough and pain in the left chest, and thick purulent secretion was aspirated from the trachea and left main bronchus.

In March, 1946, the left lung totally collapsed again. Spontaneous improvement occurred and bronchoscopy on the fourth day after admission showed only a little inspissated mucus in the trachea, which was removed by aspiration; the left bronchial tree appeared normal and the mucosa showed no significant atrophy or metaplasia or other histological change on biopsy. Bronchograms demonstrated minimal bronchiectasis in the left lower lobe.

She then remained well until 18 months later, when pain in the left shoulder was followed by cough, fever,

and expectoration of purulent sputum containing pneumococci, and a chest radiograph showed massive collapse of the left lung. She was postured and her chest thumped vigorously, when she coughed up a large mucous cast of the shape of the left main bronchus and its main subdivision. Immediate improvement of air entry on the left side was noted and was confirmed radiographically. Bronchograms later showed normal filling of the left lower lobe bronchi, demonstrating that their previous dilatation had been a reversible process resulting from temporary block.

A winter cold led to her seventh admission, in December, 1948. There was no response of the left-sided collapse to postural percussion, but three days later partial re-expansion followed spontaneous ejection of a lump of thick greyish mucus. Bronchoscopy then showed the presence of much tenacious mucus in the left main bronchus, and this was sucked away. Re-expansion remained incomplete and bronchoscopy had to be repeated a month later, when further extremely thick mucus was aspirated from the trachea and left lower lobe. Re-expansion occurred rapidly, but relief was brief and within a month the left lung collapsed completely, necessitating her eighth admission. Despite a week's intensive physiotherapy and expectorant treatment the lung did not re-expand and she had to be bronchoscoped again. The left main bronchus was found to be completely filled with thick, tenacious mucus requiring patient removal with sucker and forceps, an operation taking 45 minutes. Relief this time was immediate.

She was admitted for the ninth time in August, 1950, with partial collapse of the left upper lobe, which responded well to physiotherapy, and she completely recovered in a fortnight. She then remained well for six years apart from transient collapse of the left upper lobe treated successfully in the Out-patient Department. In December, 1956, she again developed collapse of the greater part of the left lung. After strenuous physiotherapy she coughed up a large plug of mucopurulent sputum and the lung re-expanded.

In June, 1957, she was found to have carcinoma of the cervix, which was treated with radium. She died in December of that year at the age of 80, and necropsy showed bronchopneumonia at both lung bases, with mucopurulent material in the bronchi, and carcinomatosis of liver, lungs, brain, and bones.

This patient had 14 proven episodes of pulmonary collapse at irregular intervals, all involving the left lung, and was bronchoscoped eight times. She probably had many other more transient and less severe attacks.

CASE 4.—A married woman of 66, with a history of winter bronchitis for the previous six years, developed pneumonia in February, 1958. There was an area of collapse in the lower part of the left upper lobe seen on a chest radiograph taken because cough and sputum persisted with pain around the left lower chest. A film in April still showed collapse of most of the left upper lobe, including the lingula. Tomo-

grams showed the left lower lobe bronchus to be clear but the left upper lobe bronchus appeared completely obstructed. Her sputum was negative for tubercle bacilli and other pathogens. She had further treatment with penicillin for 10 days, and after two weeks the chest film was clear. The leucocyte count was then 13,600 per c.mm., with 23% eosinophils.

In October, 1958, she had a further episode of respiratory illness, treated with penicillin and streptomycin, but a subsequent chest film showed no pulmonary collapse, and when reviewed in February, 1959, she was well and had only a little whitish mucoid sputum. The sedimentation rate was elevated, however, and a radiograph showed a small linear atelectasis in the left mid-zone. In May, 1959, she attended again, complaining of increased cough with yellow sputum for six weeks and pain and tightness in the left chest and epigastrium. She had been investigated for cholecystitis with negative result. Radiographs showed collapse of the left upper lobe and lingula, the appearances being similar to those of April, 1958. She was coughing up hard plugs of mucus with difficulty and was very dyspnoeic. Bronchoscopy showed the left upper lobe bronchus to be blocked by thick, tenacious mucus; this was aspirated and the orifices of the segmental bronchi were seen to be clear but narrowed by oedema. Biopsy of the bronchial mucosa showed a chronic inflammatory infiltrate in the submucosa. Pneumococci and haemolytic streptococci were found in the sputum, but no fungi were isolated. The white cell count was 6,000 per c.mm., of which 10% were eosinophils. Rapid re-expansion of the left upper lobe followed bronchoscopy.

A month later she had a further attack of cough and pain in the left hypochondrium, and the radiograph showed partial collapse of the lingula. Spontaneous improvement occurred and after three weeks only a small linear atelectasis remained.

She was readmitted in October, 1959, following a heavy cold, with mucopurulent sputum, pain, and dyspnoea. There were no pellets or casts in the sputum. The right upper lobe was now completely collapsed, and bronchoscopy showed that the orifice of the right upper lobe bronchus was occluded by very thick, tenacious, brownish-grey mucus. This was aspirated and the patency of the orifice restored, but the bronchus was seen to be narrowed by oedema. No tubercle bacilli were found in the aspirate but *Aspergillus fumigatus* grew on culture. Only 2% of the cells were eosinophils. Skin tests were strongly positive to mixed moulds (Bencard) and to aspergillus antigen (kindly supplied by Dr. R. W. Riddell), but no precipitating antibodies against *A. fumigatus* could be detected by Dr. Riddell in her serum. The right upper lobe did not re-expand for several days after bronchoscopy, but expansion was almost complete after physiotherapy and prednisolone had been given for 10 days. She has since had several minor attacks of bronchitis with wheezing but no further pulmonary collapse.

## DISCUSSION

Plastic bronchitis is one of the rarer bronchial diseases, and there have been only about 300 cases in the world's literature, most of them in the nineteenth century. It is also described as fibrinous, pseudo-membranous or Hoffman's bronchitis, or as bronchial croup. It was first mentioned in the second century A.D. by Galen, who thought the expectorated masses were vessels of the lung (Bettmann, 1902). It was recognized by Morgagni, who believed the casts to be composed of inspissated mucus. In 1716 Tulp described "an entire vein cast up from the lungs" and his illustration shows a bronchial cast branching to the sixth degree. Warren in 1772 described "a large polypous concretion" of the bronchus, showing that it followed exactly the shape of the bronchial tree and that it was solid and of laminated construction (Major, 1939). It affects all ages, the youngest patient recorded being 3 weeks old and the oldest 75 years. In some there is a history of preceding respiratory disorder such as bronchiectasis, tuberculosis, asthma or chronic bronchitis, or of chronic heart disease (Bettmann, 1902; Woolley, 1953; Leggat, 1954; Le Melletier and Caulet, 1958); in others, however, there has been no previous or accompanying respiratory condition, as in the fatal case reported by Johnstone (1945). Apart from pulmonary disease an association has been claimed in some instances with rheumatoid arthritis (Woolley, 1953), amyloidosis (Ranta, 1956), membranous colitis (Lamaison, 1922), enlarged thymus and also mediastinal compression by pericardial effusion (Saracoglu, 1960), although in no case on convincing evidence.

The formation of the characteristic mucous plugs can usually be traced to a combination of factors. Moderate inflammatory change in the bronchial wall is the most constant of these, which may include congestion and oedema of the mucosa, sometimes with haemorrhage, and infiltration by polymorphonuclear leucocytes, eosinophils, or lymphocytes, extending into the deeper layers. Clinical signs of infection include fever, cough with yellowish sputum, and leucocytosis. In the four patients described above the white cell count was only moderately raised, and varied from 5,100 to 15,400 cells per c.mm., reaching 21,000 on a single occasion. Mucosal biopsies showed subacute or chronic inflammatory changes. In the first patient the epithelium was flattened in places, beneath which was a moderate to heavy infiltration by lymphocytes, plasma cells and eosinophils. In the second patient biopsy was reported as showing chronic inflammation only, and in the

fourth patient there was a chronic inflammatory infiltrate in the submucosa. Biopsy in the third case was reported merely as showing no malignancy

Condorelli, Cappellini, and Rocca Rossetti (1958) described the histological findings in two collapsed lobes removed from patients with plastic bronchitis. The chief change in the bronchial mucosa was the presence of areas of epithelial flattening with zones of metaplasia in which there was an excess of goblet cells and of mucin. Inflammatory changes in the bronchial wall were relatively slight. Accumulations of mucogelatinous material were found in medium and small bronchi and in some of the alveoli; vascular changes included endothelial proliferation, subendothelial oedema, elastic degeneration, hyaline degeneration of the media, muscular hypertrophy, and numerous enlarged arteriovenous anastomoses. In the authors' view the essential lesion was not a true inflammation but a dysfunction of the bronchial mucosa, which became hypersecretory. The solidified secretion could be expectorated only with difficulty because of the absence of the ciliary ladder, which resulted from replacement of columnar ciliated epithelium by mucus-secreting cells. They considered the pulmonary vascular changes to be secondary to obstruction of the bronchial circulation.

The bacteria found in the bronchial tree or expectorated in plastic bronchitis are inconstant and not of specific aetiological significance; in our cases pneumococci, *B. friedländeri*, haemolytic streptococci, staphylococci, coliforms, neisseriae, and other organisms were isolated at various times. The possible role of *Aspergillus* is discussed below.

Occasionally the immediate cause of the bronchial irritation may be physical (as by inhalation of dust or smoke), rather than bacteriological, though these two factors may act together. A further precipitating factor may be an allergy, as in our fourth patient, who had a blood eosinophilia on two occasions and was found to be strongly sensitive to aspergillus antigen. There appears to be a close relationship to the type of bronchial asthma in which areas of segmental collapse are often found radiographically; these lesions differ from those of plastic bronchitis mainly in their more peripheral distribution. They rarely involve more than a small segment (never a lobe or lung), and the intense eosinophilia of the blood which is frequently associated with them is not characteristic of plastic bronchitis. The special features of the bronchial casts also lend support to an allergic basis, since they often have Charcot-Leyden crystals and Curschmann's spirals with large

numbers of eosinophil cells among the inspissated mucus. Seasonal factors may be important, as in our first patient, and include a repeated seasonal allergy or recurrent infection at the same time of year (Bettmann, 1902). Emotional disturbance may similarly provoke attacks; previous bronchopulmonary damage may facilitate collapse and determine its site.

Plastic bronchitis is more common in women; our four patients were women in middle age, and, of 18 cases reported recently by 10 authors, 14 were women. Plastic bronchitis may occur as a single attack without recurrence, or in attacks which may recur over a period of weeks or months and then cease, or yet again their incidence may be spread at long intervals over many years. During a bout of acute or subacute bronchitis the patient complains of shortness of breath and a feeling of suffocation, with pain in the chest and sometimes a localized wheeze. The pain is sharp, characteristically intense, constant and unaffected by respiration, and its severity in patients with extensive pulmonary collapse is of diagnostic significance. Cough is troublesome and persistent with great difficulty in expectoration, so that after much effort the patient may finally bring up plugs or casts followed by frothy or purulent mucus, which is frequently blood-stained. If the plugs are not coughed up the patient may become very ill and life may be endangered. The signs are those of bronchitis, often with localized wheezing, and there may be areas of impaired percussion note and diminished air entry which can be segmental, lobar, or involve a whole lung. A pathognomonic *bruit de drapeau* or *Ventilgeräusch* has occasionally been reported, and this is said to be caused by the flapping or vibration of loosened portions of cast in the trachea or main bronchus (Bettmann, 1902; Johnstone, 1945; Woolley, 1953). This sign may also be apparent to the patient, but it was not detected in any of our four. Radiographs during an attack will show one or more areas of pulmonary collapse, and lung abscesses may appear later from secondary sepsis. There does not seem to be a predilection for any particular part of the lung; in a series of cases reported during the last 30 years in which the side of the collapse is definitely stated, it occurred equally on the two sides. Our four patients, however, had a total of 27 observed attacks of pulmonary collapse, 25 of which occurred on the left; one patient had 14 attacks all on the left side. The radiograph is usually normal between acute episodes, but recurrent attacks may lead to fibrosis and bronchiectasis.

Bronchial casts are cylindrical, look like boiled spaghetti or macaroni, and may branch to the seventh degree. They are frequently expectorated coiled up in the form of pellets and take their characteristic shape only when floated in water. The casts usually separate quite readily from the bronchial wall, but may be difficult to cough up because of their softness, stickiness, and several bifurcations. They are normally pale greyish or greenish-white, but may be brown from altered blood. They are peculiarly tough and viscid; the surface is smooth and may reproduce the striations of the bronchial mucosa. They not infrequently contain crystals and Curschmann's spirals with eosinophils, pus cells, necrotic bronchial epithelial cells, and bacteria, which may form visible colonies. Microscopically they have a laminated fibrillary structure, and Leggat (1954) showed that the matrix contains an acid mucopolysaccharide similar to mucin, which was confirmed in our first case. Variable amounts of fibrin may also be present.

Collapse may be due to obstructive mucus: if we remember this, the possibility of plastic bronchitis will not be overlooked, though it may be difficult if there is no sputum or the sputum does not contain casts. Where the patient has produced mucous plugs in the past the diagnosis is no longer difficult. The plugs differ from those expectorated in bronchial infection by *Aspergillus fumigatus*, in which they are characteristically brownish-yellow, friable rather than tenacious, and can be shown to contain fungal mycelia on silver impregnation (Hinson, Moon, and Plummer, 1952). *Aspergillus* infection is excluded by negative skin and agglutination tests, but positive tests may be obtained in cases of sensitivity to casually inhaled fungal spores without actual mycelial infection of the bronchi. The immediate weal reaction to *aspergillus* antigen is said to be positive in about 15% of all asthmatics, and was positive in the two cases of our series in which the test was done. In only one case, however, was *Aspergillus fumigatus* obtained from the sputum and this patient differed from the others in showing a considerable blood eosinophilia. Although her serum did not show any agglutinins *aspergillus* may have played a part in producing bronchitis, asthma, and attacks of atelectasis. The casts were not examined by the silver impregnation technique in any of our four cases, but we hope to do this in future.

An acute onset with fever, dyspnoea, and purulent sputum may simulate a pneumonia, while the suppression of breath sounds may suggest pleural effusion or pneumothorax, both of which

would be excluded by full physical and radiological examination. A more difficult differentiation is from bronchial obstruction by inhaled foreign body or neoplasm, in which a careful history should help. These conditions will normally call for bronchoscopy, by which means an accurate diagnosis will be reached. Clinical points of special help in the diagnosis of plastic bronchitis are the relatively acute onset, the severity of chest pain, marked mediastinal shift, and, where present, stridor.

In general the prognosis is good, recovery from an attack usually occurring spontaneously, though the patient may be very ill and greatly distressed for several days. The prognosis is worse at the extremes of life. Fatal cases have been reported by Johnstone (1945), Woolley (1954), and Le Melletier and Caulet (1958). Necropsy of Woolley's patient, a man of 61, showed a cast occluding the right bronchial tree to the fifth subdivision and extending across the tracheal bifurcation to include the left main bronchus. Le Melletier and Caulet's patient, a woman of 32 with old-standing pulmonary tuberculosis and a thoracoplasty, was found to have a cast occupying the whole of the bronchial tree.

In mild cases the warm moistened air of steam inhalations may give sufficient relief, or a trypsin aerosol may be tried, and these measures should be combined with postural coughing and percussion. Where bronchospasm is present adrenalin and other antispasmodics may be of benefit, and corticosteroids may be helpful especially where there is a history of asthma (Pilgerstorfer, 1956). Antibacterial drugs should be given to combat infection in the collapsed lung. In all severe cases bronchoscopic aspiration should be carried out at the earliest opportunity, for by this means only can an exact diagnosis and assessment be made and speedy relief of bronchial obstruction obtained. Bronchoscopic aspiration, repeated if necessary in those cases not responding at once to simple measures, has been used by Jackson and Jackson (1934), Frank (1937), Merica (1950), and Le Melletier and Caulet (1958). In bilateral cases it may be a life-saving measure.

#### SUMMARY

Recurrent plastic bronchitis producing acute obstructive pulmonary collapse is described in four patients. Each patient required bronchoscopy on one or more occasions. The aetiology, treatment, and prognosis of the condition are discussed, and the value of bronchoscopy as a diagnostic and therapeutic measure is stressed.

We thank Dr. Kenneth Perry for the details of the first patient's original hospital admission, and Dr. Neville Oswald for the details of the second and third patients, who were under his care.

## REFERENCES

- Bettmann, M. (1902). *Amer. J. med. Sci.*, **123**, 304.
- Condorelli, A., Cappellini, G., and Rocca Rossetti, S. (1958). *Arch. Chir. Torace*, **16**, 295.
- Frank, E. S. (1937). *Maandschr. Kindergeneesk.*, **6**, 313.
- Hinson, K. F. W., Moon, A. J., and Plummer, N. S. (1952). *Thorax*, **7**, 317.
- Jackson, C., and Jackson, C. L. (1934). *Bronchoscopy, Esophagoscopy and Gastroscopy*, 3rd ed., p. 328. Saunders, Philadelphia.
- Johnstone, D. F. (1945). *Guy's Hosp. Gaz.*, **59**, 2.
- Lamaison, C. (1922). *J. Méd. Bordeaux*, **94**, 569.
- Leggat, P. O. (1954). *Dis. Chest*, **26**, 464.
- Le Melletier, J., and Caulet, T. R. (1958). *J. franç. Méd. Chir. thor.*, **12**, 237.
- Major, R. H. (1939). *Classic Descriptions of Disease*, 2nd ed., pp. 605-609. Thomas, Springfield, Illinois.
- Merica, F. W. (1950). *Ohio St. med. J.*, **46**, 1079.
- Pilgerstorfer, W. (1956). *Disch. med. Wschr.*, **81**, 1360.
- Ranta, L. J. (1956). *Pract. oto-rhino-laryng. (Basel)*, **18**, 133.
- Saracoglu, K. (1960). *Brit. med. J.*, **1**, 1548.
- Woolley, P. B. (1953). *Thorax*, **8**, 301.